

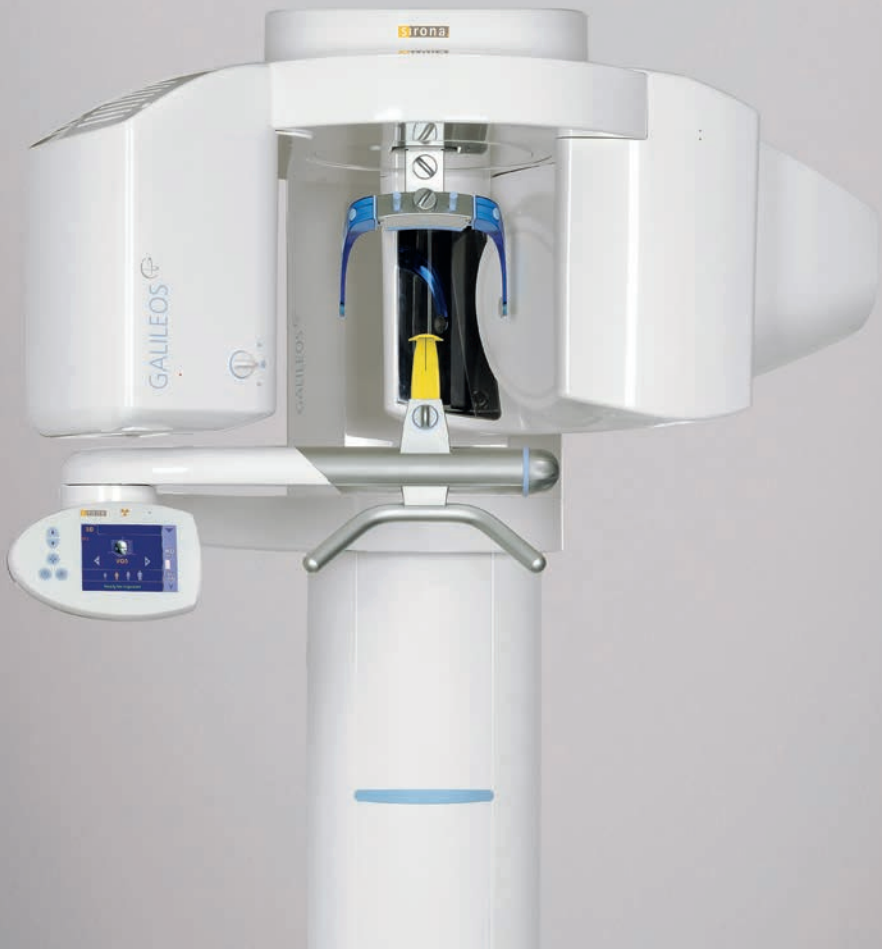THE DENTAL  
SOLUTIONS  
COMPANY™



Galileos Comfort Plus – fulfills the highest requirements.

## Cases in practice

[www.dentsplysirona.com](http://www.dentsplysirona.com)



# Content

- 03 | Jörg Haist: Editorial
- 04 | Dr. Neal Patel: Comprehensive implantology: Integration of CAD/CAM and DVT
- 07 | Dr. Tarun Agarwal: The most efficient implant workflow
- 10 | Yong-Han Koo, DDS and Domenic D'Amico, DMD: The value of safety & precision
- 12 | Jay B. Reznick, DMD, MD: Leveraging digital technology to optimize patient care
- 14 | Dr. Javier Vasquez: Advances in technology enable a movement-oriented analysis and treatment plan
- 16 | Dr. Alan J. White, DDS: 3-D imaging improves communication across patient's dental team
- 18 | August de Oliveira, DDS: Restoration of an upper pre molar facilitated by digital dentistry
- 19 | Dr. Sameer Puri: Digital dentistry along with a trial therapy gives patient his smile back
- 22 | Dr. Fernando Gutierrez-Sada: Safe predictions with transposed teeth

# Dear readers,



Dentsply Sirona is marking 10 years of digital volume tomography (DVT) - nothing less than a milestone in the development of dentistry. In hindsight, it's clear that we literally opened a new dimension for many users across dental practices and dental clinics when Galileos was launched in 2007. Since then, dentistry has become better, faster and safer.

3D diagnostics has gained considerably in importance as it not only allows generalists to achieve better findings, it also makes it easier for them to specialize through the numerous innovative options available for planning and conducting therapies. Three-dimensional imaging also supports experienced specialists in the fields of oral and maxillofacial surgery, orthodontics, and implantology in their daily treatment. Through this brochure's case study reports written by users themselves, we would like to inform you about the manifold applications of Galileos - the high-end digital imaging system from Dentsply Sirona Imaging.

As with all 3D X-ray machines from Dentsply Sirona Imaging, Galileos is synonymous with the best image quality at the lowest dose of radiation utilizing an optimal workflow. Essential to high image quality are the careful coordination of imaging

elements, and the loss-free interaction of resolution, noise suppression, and filters for metal artifact reduction. The user retains complete flexibility over the use of image data: Just one scan can generate all the relevant X-ray images.

The additional spatial information not only helps users to clearly visualize the situation, patients too understand diagnoses better and therefore opt for a suggested therapy more quickly and frequently. It is also vital not to expose patients to more than the lowest dose of radiation necessary. Dentsply Sirona Imaging is committed to this principle and therefore makes it possible to select a smaller scan volume. The latest in image intensifier technology is used for optimum results. Galileos satisfies the most stringent user requirements for general and specialized practices, as well as for clinics.

I hope you find the information and cases insightful. Thank you for your interest.

A handwritten signature in black ink that reads "Jörg Haist". The signature is written in a cursive, slightly stylized font.

Jörg Haist, Head of Product Management Imaging Systems at Dentsply Sirona Imaging

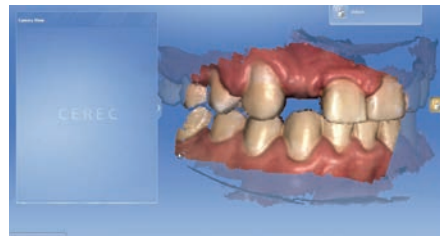# Comprehensive implantology: integration of CAD/CAM and DVT

**Author** Dr. Neal Patel

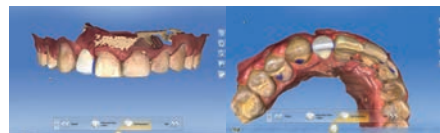
The magnitude of Sirona's GALILEOS cone beam computed tomography (CBCT) culminates with a superior quality of image teamed with the lowest possible dose of radiation. Driven by efficiency, the workflow can be streamlined while maintaining a high level of accuracy. The ability to visualize the patient's anatomic information ensures that the optimum outcome of any procedure is achieved, whether this means selecting the ideal implant size or placing it according to available bone material, all of which is made possible by GALILEOS.

Using GALILEOS, we obtained a diagnostic 3D x-ray image of a 28 year old male patient. Our patient presented with no medical contraindications, was congenitally missing tooth 7, and expressed interest in replacing the missing tooth with a dental implant. While the GALILEOS CBCT scan is being processed, the patient is seated and an optical impression is obtained using CEREC omnicam technology. The CEREC scan and 4.4 software allows the clinician to plan a virtual tooth within the missing space that is patient specific and an ideal representation of the final outcome. Once the CBCT scan and the CAD/CAM scan are

obtained, they can be combined within GALILEOS Implant Software to allow for an integrated approach for treatment planning three dimensionally. This integration addresses a comprehensive approach to implantology by allowing the clinician to evaluate the surgical and restorative phases of implant dentistry in a simple and intuitive workflow.

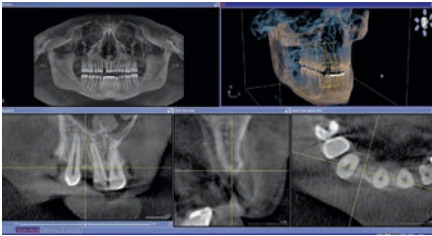


Optical impressions (a digital scan) of the case were obtained using Sirona's Omnicam and CEREC 4.4 software on the edentulous site.

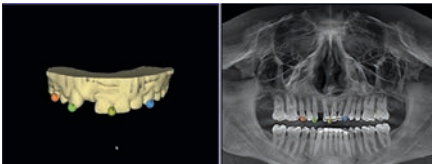


A perfect virtual tooth (digital wax-up) was designed for the patient using the CEREC 4.4 software. The virtual wax-up design was then imported as a \*.ssi file

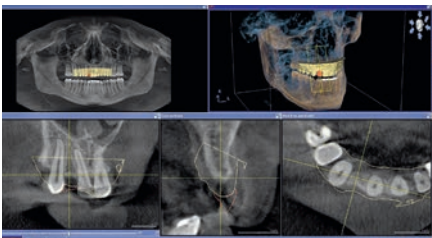
and sent to the GALILEOS CBCT reading workstation.



The GALILEOS CBCT scan provides 3D diagnostic imaging for comprehensive dentistry and diagnostics.

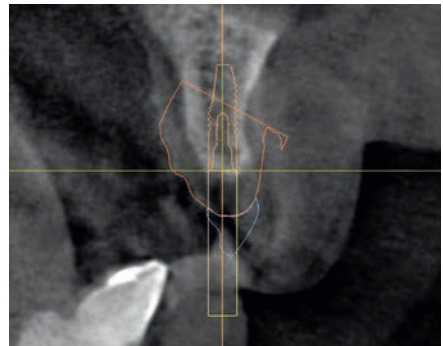


The \*.ssi file from the digital wax-up (CEREC) was integrated within the GALILEOS implant software.

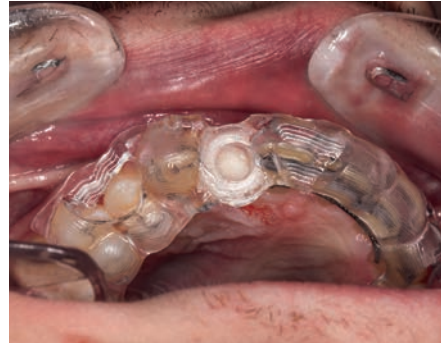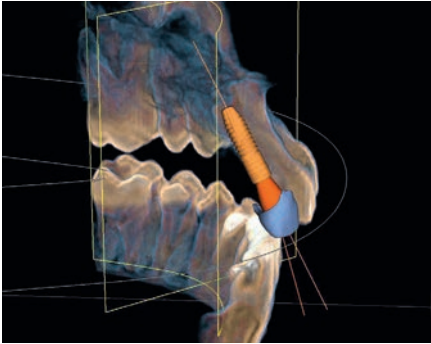


A virtual wax-up was then integrated into the CBCT scan. Integrated implant treatment planning software allows the clinician to virtually plan implant placement in 3D relative to a restorative proposal.

This cross-sectional image shows the ideal implant position relative to a virtual tooth. The integrated CAD/CAM virtual restoration includes the planned ASTRA EV implant. The clinician is able to ideally plan the implant within hard tissue with a full awareness for soft tissue anatomy and restorative potential.



The 3D visualization of the treatment plan for implant #7 allows the clinician to virtually plan the ideal implant placement, abutment plan, and potential restoration. Next, the



implant sleeve system is modified to the CEREC Guide 2 for guided surgery and the comprehensive implant plan is exported to CEREC 4.4 via a completely digital workflow. CEREC Guide Bloc maxi is selected as the definitive material for the surgical guide milling and the clinical team can then design a milled surgical guide within the CEREC 4.4 software to design and create a CEREC Guide 2. The surgical guide is then positioned within the CEREC Guide Bloc maxi disc using CEREC 4.4. The clinical team can then produce a completed milled surgical guide using the MCXL milling machine for guided implant osteotomy.

The surgical guide was then removed from the milled block, cleansed, and clinically seated for CEREC Guide 2 guided surgery. This workflow allows a precise method of implant placement by supporting a guided workflow for osteotomy. The precise implant placement leads to ideal restorative conditions for CEREC to provide a digital impression and CAD/CAM implant restoration using a tibase for the ASTRA EV system. This unique workflow is exclusive to Dentsply Sirona and streamlines 3D Implantology to benefit the patient and clinician alike.

# The most efficient implant workflow

**Author** Dr. Tarun Agarwal

The world is going digital and becoming more efficient. Dentistry is no different. Too often we believe that technology and efficiency costs more money and delivers less ideal results. This simply isn't true. To better illustrate my perspective, let's take a look at a recent implant case from start to finish.

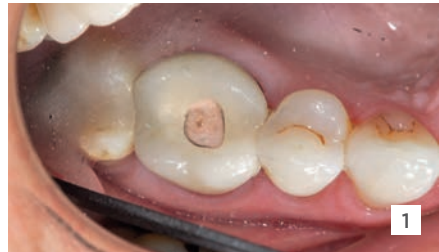The patient came to our office with pain on her upper right molar. After accessing the pulp it is discovered that the tooth is non-restorable due to vertical root fracture (Fig. 1).

Traditional implant therapy would take approximately 9-12 months for completion, involve at least 6-9 patient visits, and utilize around 4 hours of chair time. By leveraging digital technology we can complete treatment in approximately 4 months, only 3 patient visits, and achieve an excellent result in about 2 hours of chair time.

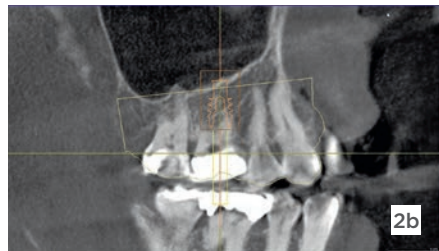
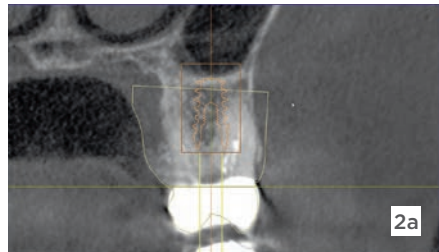## Visit 1

At this first visit (when we determined that endodontic therapy was no longer an option) we took records including a digital impression with CEREC and a 3D CBCT with GALILEOS. The planning confirmed that immediate placement was possible (Fig. 2ab).

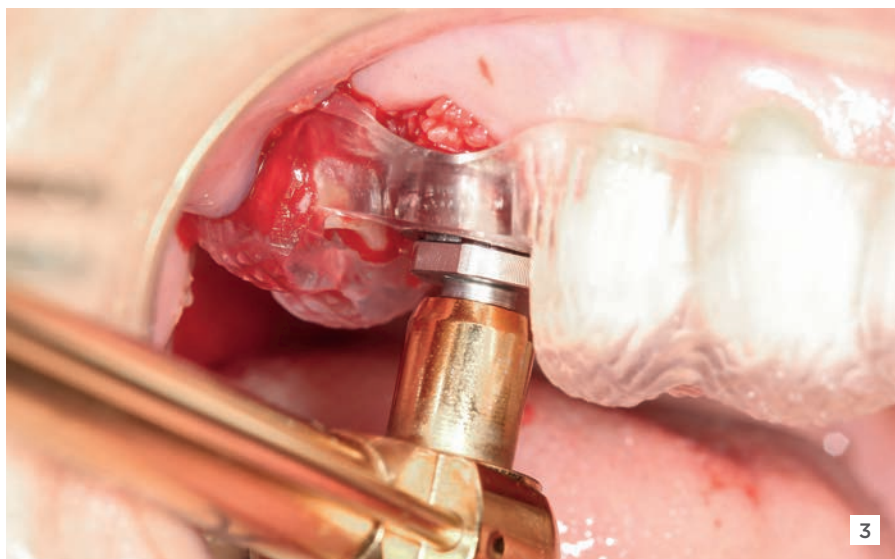One area that I have found CBCT and guided surgery immensely help-



**1** PreOperative view showing endodontic access completed in attempt so save tooth which revealed a non-restorable vertical crack.



**2ab** Slice views of virtual implant plan confirming presence of bone to allow for immediate implant placement.



**3** To prevent implant from 'walking' to path of least resistance the implant is placed through the surgical guide.

ful is the increase in cases that are candidates for immediate placement - placing implant at the same time as extraction. Having a surgical guide allows you to place an implant with precision and maximize the remaining bone for implant stability. Through the combination of the CEREC digital impression and the virtual implant planning (Fig. 3) we are able to order and/or in-office mill our surgical guide.

### Visit 2

With immediate placement it is critically important to utilize atraumatic extraction technique to preserve the bony plates and interseptal bone.

Once the tooth is removed and the sockets thoroughly cleaned the

osteotomy is completed with the guide in place. This ensures proper trajectory, depth, and bone engagement. The implant is then also placed through the surgical guide.

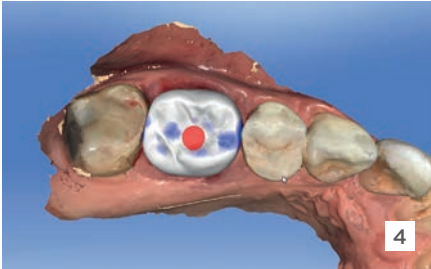
The 'gap' is grafted with your bone of choice and the site is closed to allow tissue healing and implant integration.

### Visit 3

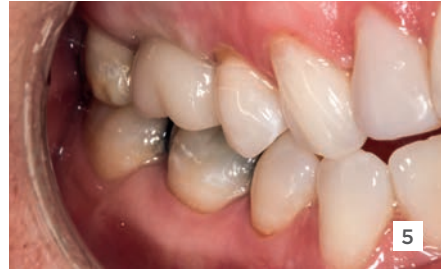After an adequate integration period of four months in immediate placement, the patient is ready for restoration. Utilizing CEREC we are able to actually take a digital impression at the time of uncover.

Immediately the final implant restoration is designed - giving the den-





**4** Final screw retained implant restoration designed to ideally support tissue.



**5** IntraOral view of final screw retained restoration in place showing ideal tissue support and emergence.

tist complete control over all aspects of restoration emergence, tissue support, occlusal scheme, and aesthetics (Fig. 4).

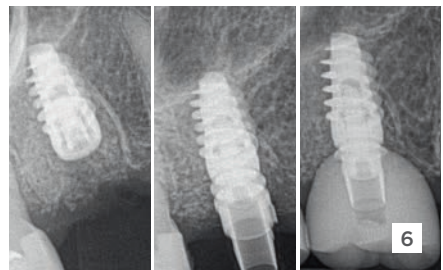
The dental assistant then crystallizes, stains, and glazes the restoration while the patient waits and comfortably watches TV, takes a nap, or gets work done. We actually like to combine their recall visit with implant delivery.

The final screw retained implant restoration is inserted and the access covered with direct resin (Fig. 5).

Here you can see radiographs of each step - immediate placement,

digital impression post, and final restoration delivery (Fig. 6).

The final result is well preserved bone, ideally supported tissue, and aesthetic implant restoration in just 3 patient visits. The result is a win-win for both the patient and the practice.



**6** Radiographs of case - immediate placement, digital impression post, and final restoration seated.

# The value of safety & precision

## 4D Guided Implantology from Start to Finish: What are the success criteria? And how do we achieve them?

**Author** Yong-Han Koo, DDS (oral and maxillofacial surgeon) and Domenic D'Amico, DMD (general dentist)

Being able to treat patients is a very special privilege that has been given to clinicians. We have an obligation to try our best to restore our patient's lost oral form and function. One of the most effective ways to do so is through the option of implant rehabilitation. Much advancement has been made to date since Dr. Brånemark's discovery of osseointegration. Yet, ironically, we have more unanswered questions and complications. The best way to handle complications is to avoid them in the first place, if possible. We need to properly diagnose the patient's condition and execute a sound treatment plan with precision.

The case below demonstrates the complete digital workflow from the diagnostic phase to the planning

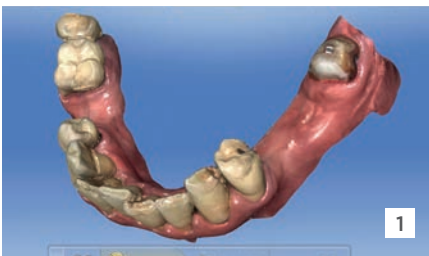and execution phases. Combined with clearly defined success criteria as our treatment goal, this digital workflow resulted in a highly esthetic and functionally pleasing outcome in a minimally invasive and efficient manner. This is what we mean by '4D guided implantology' – achieving an ideal clinical outcome utilizing 3D CAD/CAM technology combined with a 4th dimension (clear success criteria) in mind.

The key elements of long-term success criteria are the following:

1. Placement of a 3-dimensionally sound dental implant based on an ideal restorative plan.
2. Greater than 2 mm buccal bone.
3. 2-3 mm keratinized (attached) gingival tissue.

In addition, this digital workflow allows our patients to be active participants in their own treatment, understanding their own conditions as well as the risks and predictability.

A 68-year-old male with a partially edentulous span in the left posterior mandible, missing teeth Nos. 19 and 20 presents for an evaluation of implant reconstruction. He had been missing those teeth for a number of years.

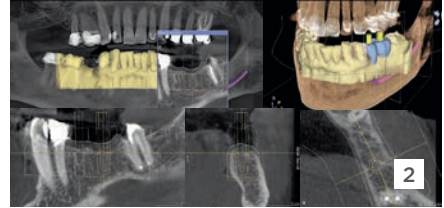


**1** Pre-op CEREC image from Omnicam, by Dr. D'Amico.

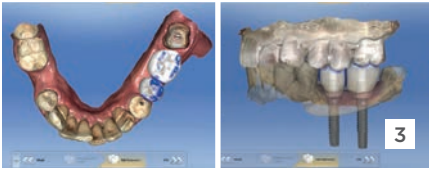
Restoratively driven, “crown down”, implantology concept was applied from start to finish. Galileos DICOM file with CEREC proposal by Dr. D’Amico was digitally transferred to Dr. Koo. Then, Dr. Koo performs virtual surgery by bringing in specific implants: Nos. 19 and 20 within the Galileos Implant software. The patient could comprehend the concept of ‘restoratively driven implantology’ utilizing digital technology in a dynamic way.

This case demonstrates the importance of establishing clear success criteria to restore lost oral form and function in a minimally invasive

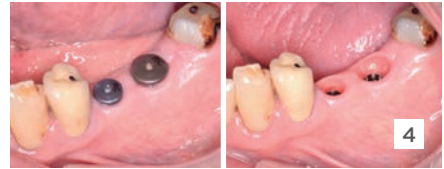manner focusing on ‘safety’ and ‘precision’ utilizing advanced digital technology.



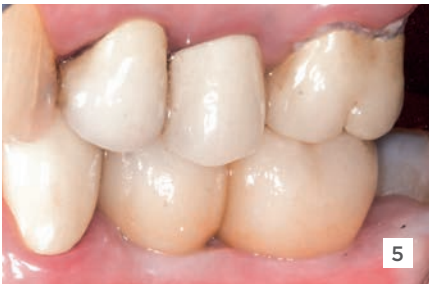**2** Incorporation of an ideal restorative plan into a digital implant proposal (reverse engineering concept via CEREC and Galileos Implant software, Dentsply Sirona, Inc.). The key elements of all three success criteria are satisfied here.



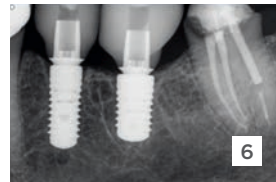**3** Total digital workflow is demonstrated from the initial phase to the final restorative phase using CEREC & CEREC MCXL Milling Unit.



**4** 2 months post-op photos. Notice the healthy quality of the gingival tissue as well as adequate emergence profile.



**5** 1 year post-op photos. Final image showing proper tissue adaptation, emergence profile and occlusal scheme.



**6** 1 year post-op radiograph shows excellent preservation of marginal bone.

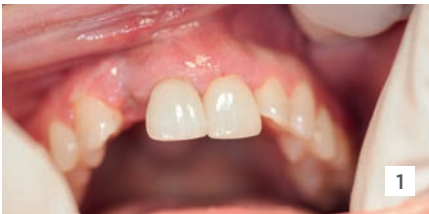# Leveraging digital technology to optimize patient care

**Author** Jay B. Reznick, DMD, MD

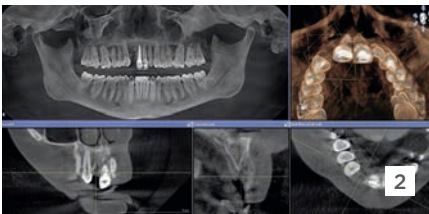
Surgeons have been treating patients with traumatic facial injuries for hundreds of years, but the accuracy with which these injuries can be evaluated, and the methods by which they can be treated have improved significantly with the evolution of 3D imaging and digital technology. Patients can also be treated more quickly and completely because of the efficiency of the work flows that integration of digital imaging, treatment planning, and manufacturing enable.

A healthy 40-year-old woman was rear-ended while driving one Sunday

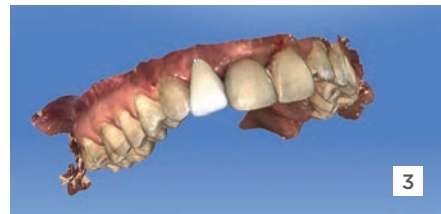afternoon. The impact did not deploy the airbag in her car, and the seatbelt did not prevent her upper teeth and lip from hitting the steering wheel. She presented to my office the following morning. Clinical exam revealed palatal displacement and mobility of the maxillary central incisors, and that the maxillary right later incisor was missing. A GALILEOS CBCT scan revealed that there was fracture of the facial alveolar bone in addition to the displacement of the teeth, and no remnant of the missing lateral incisor was seen in its socket. The treatment goal was to reduce and stabilize the subluxed teeth and alveolar bone, and to replace the avulsed tooth. Using CEREC, an optical impression of the maxillary and mandibular dental arches was obtained, and then a prosthetic proposal was generated in the position dictated by the pre-injury occlusal relationship. This “digital wax-up”



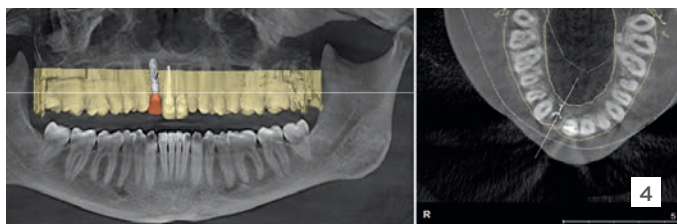
**1** Initial clinical photo.



**2** Initial Galileos scan.



**3** CEREC planning proposal.



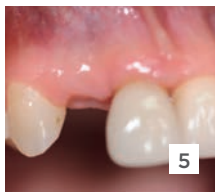**4** SICAT planning report.

was then imported in to GALILEOS Implant software to determine whether an Astra Tech System EV dental implant could be placed at the time of initial treatment, and would have enough initial mechanical stability to support a screw-retained CEREC provisional prosthesis. Due to the extent of bony injury, it was determined that the implant could be placed, but would be buried under the tissue for healing, without an immediate restoration.

The following morning, under intravenous sedation in the office, the site of the avulsed tooth was debrided, and then using a SICAT DigitalGuide, an Astra Tech System EV Straight 3.6mm diameter by 15 mm long implant fixture was accurately placed using the Astra Tech SIMPLANT Guided Surgical kit. Once the implant had been placed, Symbios Mineralized Cortical & Cancellous Granules were placed in the bony void between the top of the implant and the alveolar socket. This was covered with a resorbable collagen plug and sealed with sterile cyanoacrylate tissue glue. Next, the subluxed teeth and bone were reduced in to proper position and stabilized using an Erich arch bar and stainless steel ligature wire. Finally, with the patient under anesthesia, impressions were taken for an interim removable prosthesis.

After six weeks of stabilization, the arch bar and wires were removed. The subluxed teeth were stable, asymptomatic, and radiographically sound. The Astra Tech System EV implant integrated well, without any radiographic bone loss, and the soft tissue level was maintained. The patient is now preparing for the implant to be restored.

The integration of GALILEOS and CEREC technology allowed an accurate diagnosis of this patient's injuries and allowed me to determine what the most advantageous treatment approach would be. Freehand placement of dental implants, especially in a trauma situation such as this case, is unpredictable. GALILEOS Implant planning revealed all the variables before surgery and use of the SICAT DigitalGuide assured that the implant would be placed accurately and according to the plan. The integrated work flow facilitated getting this patient to surgery in an expedient manner and led to a successful outcome.



**5** 12 weeks post-surgery.

# Advances in technology enable a movement-oriented analysis and treatment plan

**Author** Dr. Javier Vasquez

Digital technology has advanced to the point that it is possible to make a detailed study of the jaw in motion. With GALILEOS and SICAT Function software, it is possible to use a patient's 3D cone beam scan and integrate it with actual recorded jaw motion. The application of this technology can assist in the treatment of temporomandibular joint dysfunction.

Our practice had the opportunity to work with a 26-year-old patient who presented with a significant loss of tooth structure given his relatively young age and to determine why his teeth have been grinding down. The patient did not present any symptoms aside from soreness in the jaw muscles and the need, during the day, to try to stretch them and to re-accommodate the joints with opening and lateral movements.

In the initial phase of treatment, we took a series of pictures including full-face pictures to analyze the posture of the head, intraoral images to compare centric occlusion with the patient's habitual rest position. Additionally, a series of videos was shot to analyze phonetic patterns for different sounds. We acquired additional data using the JMT device

and analyzed it in the SICAT Suite software. The analysis confirmed that the occlusion of the patient had no posterior support. Therefore, the jaw projected forward.

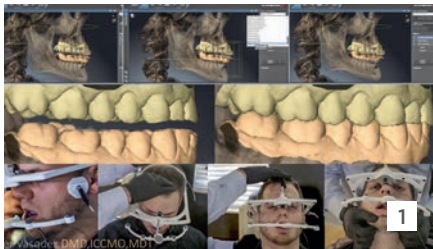
In order to take into account real mandibular dynamics such as chewing cycles, phonetics, swallowing, and mandibular reactions during head movements, fully digital therapeutic appliances – OPTIMOTION – were fabricated using CAD/CAM data. The analysis of the orthotics in connection with the digital model verified our initial clinical observations. We chose two positions from which to fabricate two bio-functional OPTIMOTION therapeutic appliances from SICAT. One was based in the best neutral position for opening and closing, while the other was based on a Nm (Neuromuscular) position with a few tenths of millimeters of discrepancy with a little lateral shift.

The patient preferred the Nm position. With the OPTIMOTION in place we measured new data and determined that it was easier to start the dynamic patterns from the new neutral position. We also demonstrated how the range motion was improved and the patient described feeling more relaxed in the face and neck.

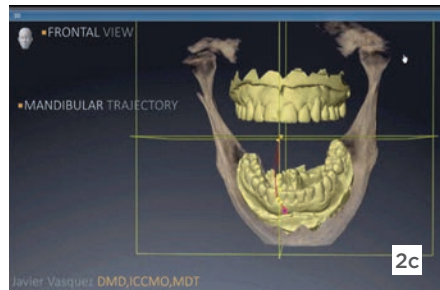
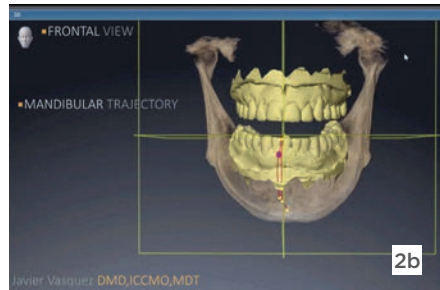
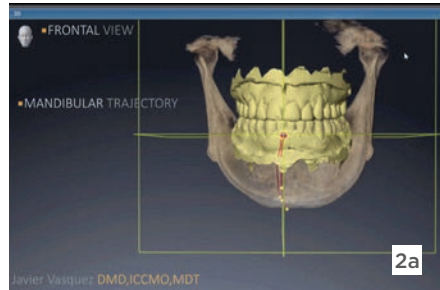
Two treatment options were proposed:

1. Functional orthopedics and orthodontics, including a maxillary three-way expander to try to develop a better position of the pre-maxilla in combination with braces to improve the arch form, three-dimensional verticalization of the lower posterior teeth with elastic, and reverse wires to support the posterior occlusion in the new position.

2. Minimally invasive restorations and soft tissue management for a final esthetic bio-functional rehabilitation. The patient ultimately opted for this latter treatment.



**1** Crano reaction analysis. Photos utilizing a JMT device and analyzed in the SICAT suite. Digital technology enables us to make a detailed study of the jaw in motion.



**2** Dynamic analysis in SICAT Funci-on software of the relationship in joint position/occlusion.

# 3-D imaging improves communication across patient's dental team

**Author** Dr. Alan J. White, DDS

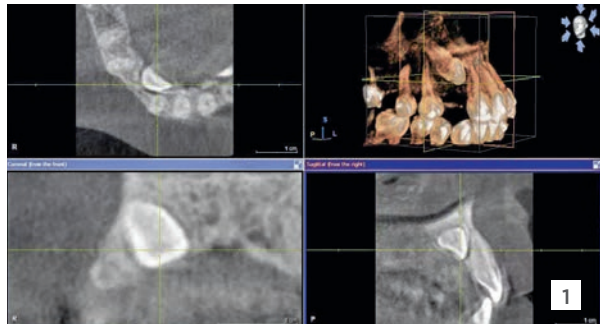
Better imaging enables better diagnosis, treatment planning, and communication which improves care. The contribution of 3D visualization to the practice of orthodontics is finally being fully appreciated. We are moving past the arguments concerning radiation dosage and cost versus diagnostic benefit as more practitioners acquire the systems and realize the benefits.

I use a Galileos Comfort Plus for every new patient exam as well as to confirm root alignment etc. prior to finishing. My ability to assess the adequacy of nasal and pharyngeal airway has resulted in many productive referrals to ENT with patient/parents motivated to follow through. Both for my TMJ (temporomandibular joints) and routine exams, being able to get a “correc-

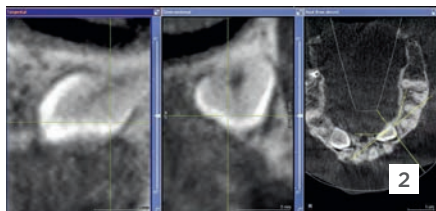
ted” tomographic view of the TMJ every time reveals and explains many issues that a simple panoramic radiograph cannot. A coronal slice of the maxillary arch showing the palatal width and molar bucco-lingual inclination makes the “expander” discussion much simpler and more definitive. True assessment of asymmetries in all three planes can be easily distinguished (This can also be helpful for proving the verity of completed procedures). That same scan can show accurate root length and morphology from any aspect and that the alveolus is often no wider than the facial-lingual width of the anterior roots.

A 3D view of an impacted cuspid will significantly impact when you treat, how you treat, surgical access,

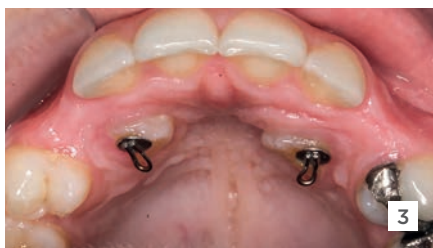**1** The Galileos scan showed bilateral palatally impacted cuspids.







**2** Unchanged position of the canines.



**3** Cuspid ready to add an elastic slingshot.

direction of guidance, the patient/parents understanding and appreciation of the problem, and will often reduce the time needed to correct the problem.

As an example, a 29-year-old female presented with multiple orthodontic issues. The most significant was bilateral palatally impacted cuspids. The patient specifically wanted Invisalign rather than traditional fixed appliances. While this may sound complicated, we do this routinely. The traditional approach would be to expose and bond a gold chain to the impacted teeth and begin traction towards an archwire engaged in fixed brackets. For traction towards an aligner, the tooth needs to have erupted vertically first before moving laterally. I requested exposure as per the protocol recommended by Kokich from the University of Washington at Seattle, specifically an exposure of sufficient width as to remove all bone that might impede eruption. A Caplin hook was added to hold perio pack initially and to provide an attachment for elastics later. After 6 months it was

evident that the teeth had not moved since the time of their exposure. I took a new Galileos scan and it was evident that there was still bone surrounding the crowns that was impeding eruption. The patient returned to the Oral Surgeon with visual evidence that further bone needed to be removed. The Oral Surgeon had initially been reluctant regarding the need for additional bone removal, feeling that it was the lack of traction that had delayed eruption, until she saw the CBCT images.

Six months after the removal of the bony lip around the exposure, the cuspid are now ready to add an elastic slingshot to the patient's aligner to move the teeth labially. After the crown is moved into position a new CBCT will be taken to design the force systems to move the roots into position.

As a Galileos user for nearly ten years, I cannot imagine attempting to provide the same level of care without this critical technology.

# Restoration of an upper premolar facilitated by digital dentistry

**Author** August de Oliveira, DDS

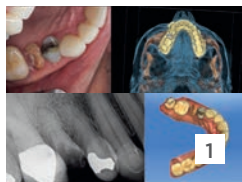Single visit restorations are becoming increasingly popular as patients appreciate their convenience. Digital imaging helps to achieve accurate results ensuring that restorations are placed in the most ideal positions.

Recently, a patient came in with a broken off tooth – an upper premolar that had broken off and clearly required restoration. This is a

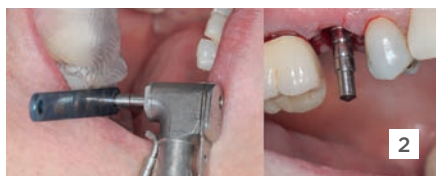fairly common tooth needing restoration. I took a full arch scan using the CEREC camera and combined that with 3D imaging via GALILEOS. By combining the GALILEOS and the CEREC scans I was able to place the implant in the most ideal restorative position. The GALILEOS scan showed exactly where the patient had the most bone for stability.

As long as the Guide Sleeve and Platform are coronal to the tooth fragment you can do the case without extracting first. Surgery was made easy using CEREC Guide 2. This is a great system for immediate restorations.

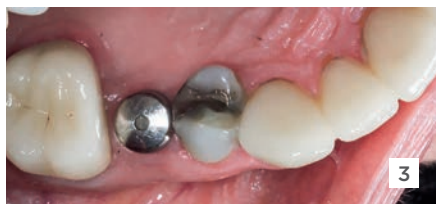Given that the gap distance was less than 2 mm, no graft was required so I placed a large cylindrical healing abutment. The patient returned after 6 months. I used an e.max screw retained crown. After some hand polishing and staining, the end result turned out decently with a satisfied patient.



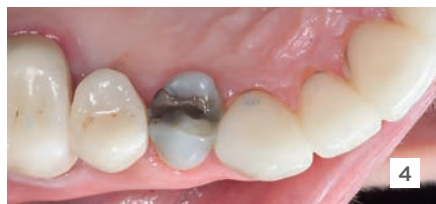**1** As seen in the image on the lower left, tooth # 13 is in need of restoration.



**2** Utilizing CEREC Guide 2.



**3** Cylindrical healing abutment.

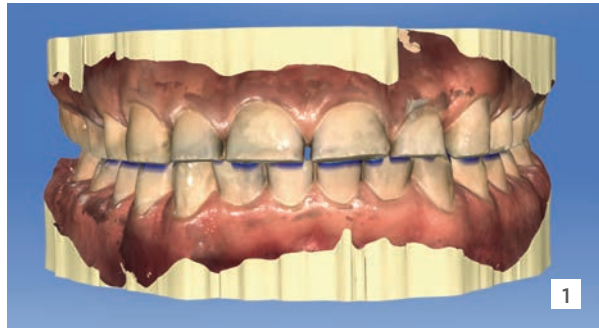


**4** e.max screw retained crown after polishing and staining.

# Digital dentistry along with a trial therapy gives patient his smile back

**Author** Dr. Sameer Puri

**1** The maxillary and mandibular arches were scanned in the CEREC Ortho software to take advantage of the dual buccal bite and accurate occlusal rendition.



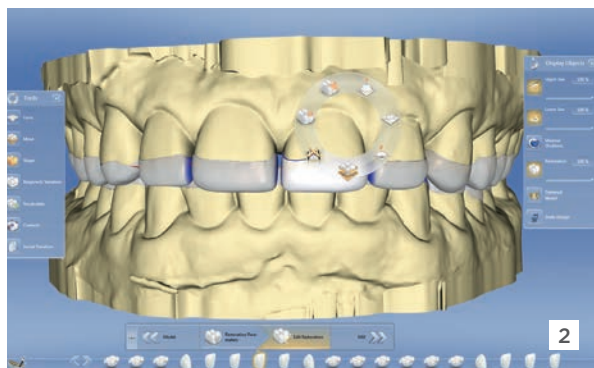
A 35-year-old patient with a history of bruxism presented to our clinic for treatment. Clinical examination showed uniform wear of the teeth, and loss of vertical dimension of occlusion. The patient also showed no tooth display at a lip-at-rest position, confirming the severe wear of the teeth. Clinical and radiographic examination showed no other pathology or decay other than the significantly worn teeth. The patient's desire was to have his teeth restored to a normal-sized dentition.

Capturing a lip-at-rest photo is critical for determining the final position of the teeth. In a wear case such as this, if the patient's existing incisal edges are 0.5 mm below the lip, and we make the determination that our desire is to have the patient show approximately 1.5 mm of tooth at

rest, then the plan involves adding approximately 2 mm of tooth structure to the incisal edges. A brief summary of the treatment plan would indicate that we need to determine the position of the incisal edges of the maxillary centrals, and then open the vertical dimension of occlusion to compensate for the increased vertical. Once the incisal edges of the incisors are determined, the occlusal plane in the posterior is leveled, and the lower teeth are brought into occlusion to fit.

The plan was to restore the patient initially using the CEREC system and, with milled composite restorations, perform a trial therapy. If the esthetic and functional needs of the patient were satisfied in the trial therapy, then the composite bonded interim restorations would

**2** After verification of the vertical opening, the remaining proposals were rendered by the software.



eventually be converted to final, all-ceramic restorations.

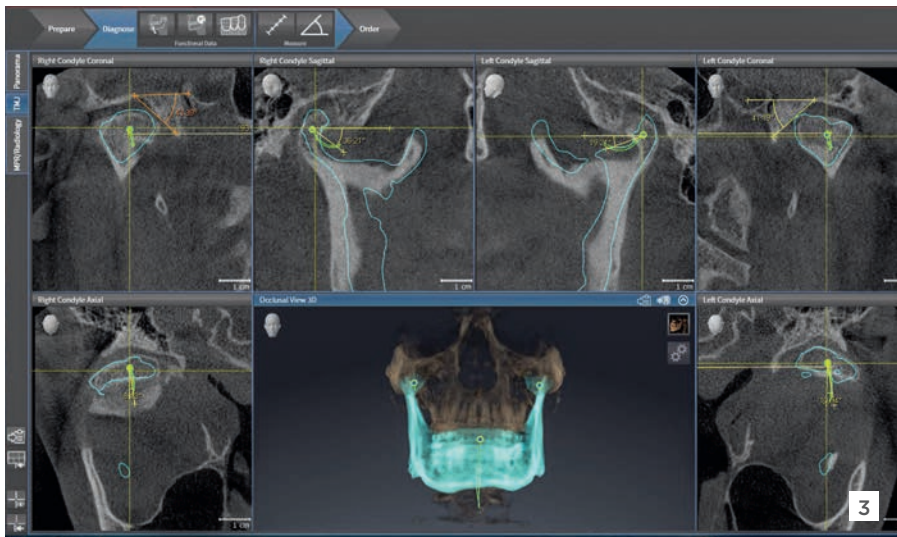
The patient was scanned using the CEREC Ortho software in a centric relation position so that an accurate rendition of the upper and lower jaws with the joints in a seated position could be captured. After rendering the file, the scan was then imported in the CEREC chairside software for final design of the restorations. Teeth #3 to #14 (upper first molar to upper first molar) and teeth #19 to #30 (lower first molar to lower first molar) were designated as veneers and onlays.

Utilizing the CEREC virtual articulator, the incisal pin was opened to allow for the increased length of the teeth. After opening the vertical dimension, maxillary and mandibular anterior teeth were marginated and initial preparations in the anterior were rendered. Since this is a trial therapy, no preparation of the teeth was completed, and the margins were placed on unprepared teeth. By designing only the ante-

rior teeth, the final esthetic determination as well as accuracy of the opening of the vertical dimension of occlusion was completed. Evaluation of the amount of opening for the posterior teeth was also finalized based on the anterior esthetics.

After finalizing the anterior proposals, the posterior teeth were marginated and final proposals were rendered by the software. While no teeth were prepared, the restorations were carried on the lingual surfaces of the teeth so that some stability could be achieved when seating the restorations. A photo of the patient can be imported into the CEREC software and superimposed over the proposals. This serves as a confirmation that the proposed incisal edge length is not excessive.

Prior to milling final restorations, the patient's cone beam scan was opened in the SICAT Function software, and the data from the Joint Motion Tracking was imported and integrated. This data allowed the author to capture the settings for program-



Patient's cone beam scan was opened in the SICAT Function software, and the data from the Joint Motion Tracking was imported and integrated.

ming the virtual articulator. The advantage of the GALILEOS scan is that the exact numbers needed to program the CEREC virtual articulator can be extrapolated precisely from the cone beam scan and the JMT readings. These numbers, once recorded in the SICAT software, were programmed into the virtual articulator for the patient in the CEREC software, and all the restorations were adjusted according to the settings and were sent to the milling unit.

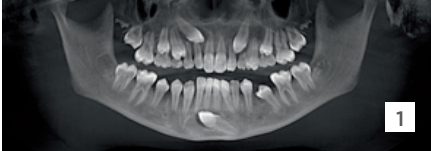
After milling the restorations, the veneers on the anterior teeth were seated first with a filled flowable resin. The high translucency of the materials allowed the restorations to be seated with minimal esthetic compromise. After seating upper anteriors and lower anteriors, the occlusion in the anterior was finali-

zed in both centric as well as excursive movements, and any necessary adjustments were made. The goal was to have a balanced occlusal scheme with cuspid rise and balancing contacts on crossover. By only having to deal with the anterior teeth at this point, it allowed for a quicker refinement of the occlusion.

Once the occlusion was finalized on the anterior teeth, the posterior teeth were bonded in place and the occlusion finalized for the entire mouth. Final evaluation of the teeth showed appropriate lip-at-rest display and a more harmonious smile. This trial therapy has resulted in a significant change in the appearance of the patient and the case demonstrates the potential of CEREC in a fully digitally treated case with no analog impressions or models whatsoever.

# Safe predictions with transposed teeth

**Author** Dr. Fernando Gutierrez-Sada



**1** Several transposed teeth are apparent from the X-ray image.

**Transposition of teeth can occur in the entire dentition and impair their natural development, arrangement and condition. The canine and incisor regions are especially affected. Investigation of the spatial arrangement and anatomical relationships of the dentition help to predict the feasibility of treatment and plan effective therapy.**

Over the course of human evolution, dietary habits and consequently the anatomy of the jaw have changed significantly. The human jaw has become smaller over the millennia, which may lead to problems such as transposed teeth. This is not an uncommon situation in the orthodontic practice. Transposed teeth often do not erupt, but instead push obliquely against the roots of neighboring teeth and compromise them. The therapy of choice for impacted teeth is elimination of eruption obstacles. However, in many cases orthodontic therapy is necessary to

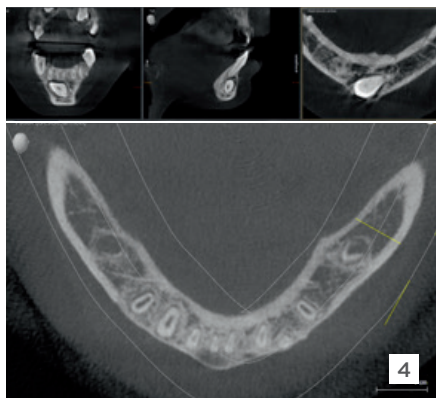
elongate the impacted tooth and correctly set it in the dental arch.

The advantage of the DVT technique with such indications is the high explanatory power of the X-ray volume. Besides the familiar panorama view, a single 3D scan with Orthophos 3D or Galileos also facilitates the representation of further sections that usually clearly demonstrate the findings. Visualization of the neighboring structures helps find solutions for the diagnosis and surgical planning. This is explained in more detail in the following case study involving an 11-year-old female patient.

A panoramic X-ray ascertained the patient had transposed teeth. Using Galileos we took a DVT with a 15 cm field of view to render a virtual reconstruction and to visualize the exact position and anatomical relationships (Fig. 1). It revealed that canine 13 was in a highly transposed position and its crown was located between the roots of teeth 11 and 12 (Fig. 2). The relationship to the right nostril was identifiable from the axial view (Fig. 3). Tooth 23 showed a slightly retarded eruption, but its position was upright (Fig. 4). Furthermore, it became evident that the lower left canine, 33, was transposed and had transversed the mandibular symphysis region

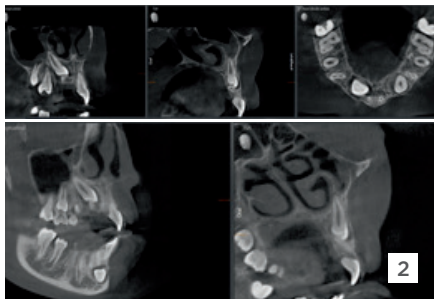
vestibular to the roots of the teeth (Fig. 5 and 6).

This clearly identifiable finding from the 3D image facilitated the decision-making process and enabled us to develop the treatment plan and to predict a good outcome. As canine 33 was not viable, we decided to pull it. It was also assumed that tooth 23 would fall out and make space for teeth to grow into.

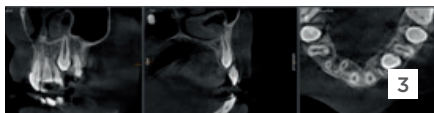

**4** Canine 33 cannot be saved.

Transposed tooth 13 was to be pulled to the front by using a device attached to the dental crown. The course of therapy was monitored from a new DVT after six months, whereby a satisfactory outcome was shown.



**2** The axial view shows the extension of tooth 13.



**3** Tooth 23 has not yet erupted through the gingiva, but is upright.

#### Publisher

Dentsply Sirona  
Sirona Straße 1  
A-5071 Wals/Salzburg (Austria)  
E-Mail: [contact@dentsplysirona.com](mailto:contact@dentsplysirona.com)  
Telefon: +43 (0) 662 24 50-0  
Telefax: +43 (0) 662 24 50-510  
[www.dentsplysirona.com](http://www.dentsplysirona.com)

#### Responsible under German press law

Vincent Kummer, Marion Par-Weixlberger,  
Dentsply Sirona, in Wals/Salzburg  
(Austria)

#### Editorial and design

Edelman.ergo GmbH  
Agrippinawerft 28  
D-50678 Köln  
[www.edelmanergo.com](http://www.edelmanergo.com)

#### Special thanks also to:

Dr. Tarun Agarwal, Domenic D'Amico, DMD,  
Dr. Fernando Gutierrez-Sada, Yong-Han Koo,  
DDS, August de Oliveira, DDS, Dr. Neal Patel,  
Dr. Sameer Puri, Jay B. Reznick, DMD, MD,  
Dr. Javier Vasquez, Dr. Alan J. White, DDS

#### Printing

schmitz druck & medien GmbH & Co. KG  
Weiherfeld 41  
D-41379 Brüggen  
Telefon: +49 (0)2163-95093-0

We reserve the right to make technical  
modifications, typographical errors  
and mistakes.

**Better sleep today for a better tomorrow!**



## Fully digital appliance-based treatment of obstructive sleep apnea

SICAT Air and **OPTISLEEP** are the first 3D solution for the visualization and analysis of the upper airway and appliance-based treatment of obstructive sleep apnea – fully digital and intuitive:

- Direct visualization of constrictions and simplified patient communication
- Fully digital planning and manufacturing for a more efficient workflow
- Thin design for a natural feel

The combination of SICAT Air and **OPTISLEEP** helps your patients get the uninterrupted sleep they deserve – for more information visit [WWW.SICAT.COM](http://WWW.SICAT.COM).



 **OPTISLEEP**

BETTER TECHNOLOGY. BETTER SLEEP.



A91100-M147-C074-01-7600