

JIRD[®]

JOURNAL OF IMPLANT AND RECONSTRUCTIVE DENTISTRY[®]

www.JIRD-online.com



Special issue:

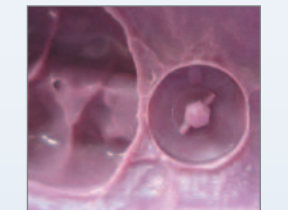
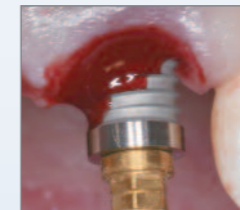
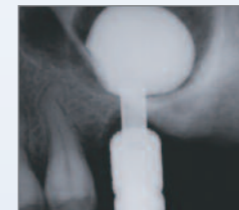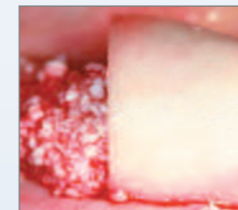
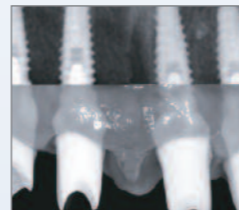
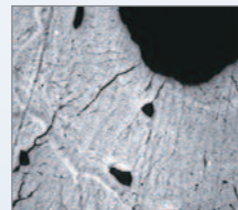
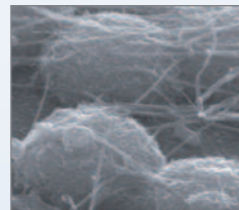



The Gothenburg
Research and Technology Forum

A **BIOMET 3i**™ Publication

2010 Vol. 2 | No. 1

Table of Contents



pg. 4
Program
Director
Prof. Dr. Tomas
Albrektsson,
SWEDEN

pg. 7
Editorial:
The artistry of
aesthetic dentistry
Dr. Konrad Meyenberg,
SWITZERLAND

pg. 9
Editorial:
Implant stability
and tissue preservation
Prof. Lars Rasmusson,
SWEDEN

pg. 10
Immediate loading:
The role of the
implant surface
on biological
stabilization
Prof. John E. Davies,
CANADA

pg. 18
Editorial:
Clinical factors
related to implant
stability with
tapered implants
Prof. Tiziano Testori,
ITALY

pg. 25
Editorial:
Predictable guided
bone regeneration
Prof. Markus B. Hürzeler,
GERMANY

pg. 26
The use of minimally
invasive antral membrane
balloon elevation
(MIAMBE) to treat
the posterior maxilla:
A clinical presentation
Dr. Ziv Mazor
ISRAEL

pg. 32
Using immediate
implant placement
to address aesthetic
and biomechanical
challenges: A clinical
presentation
Prof. Pär-Olov Östman,
SWEDEN

pg. 39
Editorial:
The age of
digital dentistry
for practical
and aesthetic
prosthetic solutions
Prof. Anders Örtorp,
SWEDEN

pg. 40
Increasing implant
dentistry in
undergraduate
education using
new technology:
A pilot project
Prof. Hugo De Bruyn
& Dr. Stefan Vandeweghe
BELGIUM

Publisher's Info



EDITORIAL TEAM

Editor Emeritus
Richard J. Lazzara, DMD, MScD

Editor
Anita Daniels

Clinical Editors
Harold S. Baumgarten, DMD
Carl J. Drago, DDS, MS
John A. Lupovici, DDS
Alan M. Meltzer, DMD, MScD
Pär-Olov Östman, DDS, PhD
George F. Priest, DMD

Research Editor
J.E. Davies, BDS, PhD, DSc

Medical Illustration
Robin deSomer Pierce, BSMI
Joseph Gorman

Design
FCEdge

Web Design
Tim Doherty
Rob Barrett

The Journal of Implant and Reconstructive Dentistry (JIRD) is published by BIOMET 3i LLC, 4555 Riverside Drive, Palm Beach Gardens, Florida, USA 33410. Telephone: 561.776.6700. Bone Bonding, CAM StructSURE, Certain, Encode, EP, GingiHue, Gold-Tite, JIRD, Journal of Implant and Reconstructive Dentistry, PreFormance, OsseoGuard, OSSEOTITE, PREVAIL, and ZIRReal are registered trademarks and NanoTite and Navigator are trademarks of BIOMET 3i LLC. BIOMET is a registered trademark and BIOMET 3i and design are trademarks of BIOMET, Inc. Endobon is a registered trademark of BIOMET Deutschland GmbH. ©2010 BIOMET 3i LLC.

Opinions expressed in the articles and communications in both print and on the JIRD website are those of the authors and not necessarily those of the Editor(s) or Publisher. The Editor(s) and Publisher disclaim any responsibility or liability for such material. The clinical techniques presented in JIRD are representative of the individual clinician's experience in clinical practice and may not be indicative of other clinical cases or outcomes due to varying patient subsets and clinical scenarios. Reading an article in JIRD does not necessarily qualify you to integrate new techniques or procedures into your practice. JIRD expects its readers to exercise judgment regarding their expertise and, when necessary, recommends further education prior to the implementation of any new procedure.

EDITORIAL ADVISORY BOARD

- Crawford Bain, DDS (SCOTLAND)
- Carlo Bianchessi, MD, DDS (ITALY)
- Michael Block, DMD (USA)
- José Luís Calvo-Guirado, DDS, PhD, MS (SPAIN)
- Joseph R. Carpentieri, DDS (USA)
- Stephen J. Chu, DMD, MSD, CDT (USA)
- Roberto Cocchetto, MD, DDS (ITALY)
- Mithridade Davarpanah, MD (FRANCE)
- Robert A. del Castillo, DMD (USA)
- Robert W. Emery, DDS (USA)
- Israel M. Finger, BDS, MS, M. Ed, DDS (USA)
- Ronnie J. Goené, DDS (NETHERLANDS)
- Ueli Grunder, DMD (SWITZERLAND)
- Robert L. Holt, DMD, PhD (USA)
- Markus Hürzeler, DMD, PhD (GERMANY)
- Juan Carlos Ibañez, DDS (ARGENTINA)
- Curtis E. Jansen, DDS (USA)
- Gregory J. Keiser, DMD (USA)
- Perry R. Klokkevold, DDS, MS (USA)
- Robert M. London, DDS, (USA)
- Robert Marx, DDS (USA)
- Ziv Mazor, DMD (ISRAEL)
- Richard A. McCall, DDS MS (USA)
- Konrad Meyenberg, DDS (SWITZERLAND)
- Craig M. Misch, DDS, MDS (USA)
- Gary A. Morris, DDS (USA)
- Rich Napolitano, CDT (USA)
- Keith Progebin, DDS (USA)
- Alan L. Rosenfeld, DDS, FACD (USA)
- Bruce E. Rotter, DMD (USA)
- Anthony G. Sclar, DMD (USA)
- Michael K. Sonick, DMD (USA)
- Tiziano Testori, MD, DDS, FICD (ITALY)
- Xavier Vela-Nebot, MD, DDS (SPAIN)
- Lee R. Walker, MD, DDS (USA)
- Stephen S. Wallace, DDS (USA)
- Stephen L. Wheeler, DDS (USA)

Prof. Dr. Tomas Albrektsson

Program **director**



It was a great pleasure for me to serve as director of the Gothenburg Research and Technology Forum, sponsored by BIOMET 3i and conducted in association with the Sahlgrenska Academy of the University of Gothenburg. The forum provided an opportunity to reflect upon the myriad of developments that have occurred since the study of osseointegration began back in the 1960s and to discuss current research that promises to usher in more exciting breakthroughs in the future.

Treatment with implants has expanded in so many ways. What at first was a tool restricted to researchers is now helping millions of patients worldwide. Complex protocols have been simplified and improved. Treatment indications continue to widen, and understanding of implant biomechanics continues to be refined. Whereas once we were able to study implants only at the millimeter level of resolution, microscopes later enabled the study of implant surfaces at the micrometer level. Now research is investigating whether even nanometer indentations can impact clinical results.

Looking further ahead, I can foresee a day when alternative ways of securing and stabilizing implants may be found. But with five-year clinical success rates for osseointegration typically ranging between 95 and 100%, it's difficult for me to imagine that osseointegration will ever be completely supplanted as a means of anchoring implants in human bone.

The reports on the following pages provide insight into some of the exciting developments and research findings presented at the forum. They support my conviction that the field of implant dentistry remains as exciting today as it was 40 years ago.

Prof. Dr. Tomas Albrektsson
Department of Biomaterials
Institute for Clinical Sciences
Sahlgrenska Academy
University of Gothenburg

Dr. Z. Mazor
ISRAEL

Prof. T. Testori
ITALY

Dr. K. Meyenberg
SWITZERLAND

Prof. P.O. Östman
SWEDEN

Dr. X. Rodriguez
SPAIN

Prof. S. Renvert
SWEDEN

Dr. S. Vandeweghe
BELGIUM

Dr. D. Caspar
FRANCE

Prof. J. E. Davies
CANADA

Prof. J. Calvo-Guirado
SPAIN

Dr. O. Zuhr
GERMANY

Prof. H. De Bruyn
BELGIUM

Prof. M. Hürzeler
GERMANY



UNIVERSITY OF GOTHENBURG

The Gothenburg Research And Technology Forum

Gothenburg, Sweden

Program
director &
moderators

Prof. A. Örtorp
SWEDEN

Prof. L. Rasmusson
SWEDEN

Prof. T. Albrektsson
SWEDEN

Prof. J. Wennström
SWEDEN

The artistry of aesthetic dentistry



Konrad Meyenberg, DMD
Private Practice
Zurich, Switzerland

Being a prosthodontist is a little like being the director of an orchestra. What the patient sees after extensive treatment in a complex case is what the prosthodontist does. But our work relies on what the periodontist, the implantologist, the orthodontist, the dental technician, and the patient all have contributed. We create something out of all these components; a lot of communication is involved. Even though patients in most cases think the final result depends on what we as prosthodontists have done, it is an effort that depends upon the contributions of each member of the team.

For me, part of what makes dentistry so fascinating is the aesthetic component. One needs to know a lot about sculpting, colors, and shapes so that together with the patient and the dental technician, the definitive aesthetics can be developed. That is why I say the role of the prosthodontist is like that of a director. The prosthodontist should be involved from the beginning. He or she should plan the entire case because ultimately the responsibility rests on the prosthodontist's shoulders.

I also teach, and I do that because I want to learn. I learn probably more from the people I teach than they learn from me. If one knows that multiple clinicians and laboratory technicians will be involved in a given case, one probably will have a different approach to it from the beginning. Clinicians should look at everything as if they were looking through the eye of a camera lens: always asking, "Is this good enough?" I have learned a lot by taking photographs because it forces me to pay more attention to details. Discussing the case later with colleagues also makes one aware of details that may have previously escaped attention. Dentistry is a constant learning experience, which is good because as one gets older, one might lose the ability to do some things. But it is also true that with age, one gains experience. With experience, clinicians see more and more, and they may gain the ability to perform complex procedures in shorter periods of time.

Now that I have had 25 years experience in treating complex clinical scenarios, I think the most important thing is to define from the beginning the results one expects to achieve. Expectations for clinicians, laboratory technicians, and patients must be clearly defined. My colleagues and I, who have acquired a lot of experience over the years, have learned what is possible and what is not possible. Initially we thought everything was possible. We may have treatment-planned patients with multiple surgeries without paying too much attention to what this meant for each patient.

Today, we try to plan for treatments that are much more efficient and less invasive. We think not only about what is the most predictable way to achieve an excellent final result but also about what is most supportable from the patient's point of view. For example, today we are evaluating from the beginning whether or not we can rebuild soft tissue. Very often in complex cases, we are coming to the conclusion that less treatment is more. Compensating for soft-tissue deficiencies with pink porcelain is an interesting option that was forgotten for a while. But when I look at articles in

renowned journals by international top-level dentists, more and more I see this presented as a serious alternative to extensive surgical procedures.

Today, we are working with different concepts and implant components. In the future, I expect we will see further simplification of procedures. It is not easy to analyze different treatment options and determine which are the most efficient to achieve an aesthetically pleasing result. Computer-aided design and manufacturing (CAD/CAM) technology, which in some areas is still in its infancy, will continue to evolve and have a major impact on dentistry in the future. For one thing, I hope that in the future, CAD/CAM systems will be compatible with one other. That way everyone in the office could use the same scanner to obtain digital information that can be used in development of casts, copings, abutments, and crowns. This will involve behavioral changes in clinicians and laboratory technicians. Future modifications should allow us to save time and money. Ultimately, clinicians and technicians will still be responsible for developing optimal aesthetics, even though the restorations may be made with CAD/CAM technologies.



About The Cover Art: It was both a challenge and a pleasure to create the cover illustration for the current edition of JIRD. I knew that all the authors in this issue would be inspiring readers with their ideas and research. Both science and clinical work require a lot of creativity, and I wanted the cover to reflect this relationship. I wanted to address the biologic environment we all work in, so it had to be water. I envisioned one being at home in that environment and feeling perfectly at ease. Who better than a mermaid? To be able to play is one of the essential gifts, so I wanted to depict her playing, drawing inspiration from some of the tools on the sea bed.

Implant stability and tissue preservation



Lars Rasmusson, DDS, PhD
 Professor of Maxillofacial Surgery
 Dept. of Oral and
 Maxillofacial Surgery
 The Sahlgrenska Academy
 University of Gothenburg
 Sweden


The topic of osseointegration in conjunction with bone grafts is very interesting. Previous studies conducted by our group have confirmed that platelet-rich plasma affects early healing response around implants. However, that effect appears to be brief. Researchers have proven in numerous studies that the effect of local growth factors probably lasts for only minutes or hours, and the effect in the healing process histologically can be seen for only three to four months. After six to twelve months, it is no longer detectable.

We have therefore moved to a more simplified treatment protocol. We are now using a technique for making a membrane from the patient's own blood. In this technique, blood is harvested from the patient who will be receiving a bone graft. The blood is allowed to coagulate; a platelet-rich fibrin membrane is produced from the coagulated blood. The membrane is used to cover the bone graft. Using monoclonal antibodies and other tools, we are now studying what happens when the platelets are subjected to this kind of handling. The aim is to determine whether platelets still continue to release growth factors that function normally or whether the processing inactivates the platelets to any extent.

The other facts that are important to consider are the costs and benefits of this kind of treatment. For the healthy elderly patient who has merely lost some teeth and bone, I believe that a careful cost-benefit analysis may not justify the additional therapeutic steps. Patients who have been treated for a malignancy with chemotherapy or even radiation to the head and neck region experience impaired vascularity. This may also impact patients with diabetes, peripheral vascular disease, or autoimmune disease. For these patient populations, the benefits of using platelet-rich concentrates to enhance healing are much more likely to justify the additional cost.

Immediate loading: The role of the implant surface on biological stabilization

John E. Davies, BDS, PhD, DSc



Clinicians who are immediately restoring and loading dental implants must consider a hierarchy of clinical parameters, including the choice of the implant surface. The latter plays a crucial role in orchestrating many of the cellular mechanisms in peri-implant tissue healing. The phenomenon of bone bonding is also critically dependent upon the design of the implant surface. This article reviews the cascade of post-placement healing responses and examines the role of implant micro- and nanotopography within that sequence of events.

Key Words: implant surface, biologic stabilization, bone bonding, nanotopography, osteogenesis

Introduction

Treatment planning is of cardinal importance in clinical procedures. When placing dental implants, consideration of parameters such as the dental base relationship, occlusion, and planned implant positioning with respect to the residual alveolar bone are all critically important, while surgical technique can also dramatically affect the therapeutic outcome. Similarly, the three-dimensional design of the implant (the gross dimensions and shape, including screw thread design) significantly influences the biomechanical environment created upon implant placement. Finally, increasing the complexity of the implant surface microtopography has been recognized for more than a decade to profoundly affect healing, particularly in cancellous bone.

important it is for clinicians to pay careful attention to each aspect of this hierarchy. This is particularly true when immediately restoring and loading endosseous dental implants, an increasingly popular approach to the rehabilitation of edentulous patients.

Early studies of occlusal loading of immediately placed implants reported bone loss due to excessive implant micromotion¹ and the formation of a fibrous peri-implant connective tissue layer.² However, more recent studies have documented a high level of bone-to-implant contact in humans around immediately loaded implants.³ Over the past 10 years, immediate loading therapies have shown success rates ranging from 97% to 100% with comparable or better histological and histomorphometric outcomes than delayed loading protocols.⁴

Figure 1 illustrates this hierarchy of clinical parameters. The more advanced the implant procedure, the more

John E. Davies, BDS, PhD, DSc (continued)

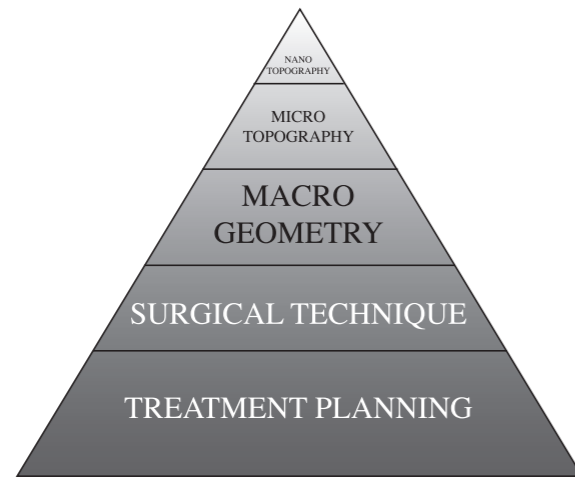


Fig. 1

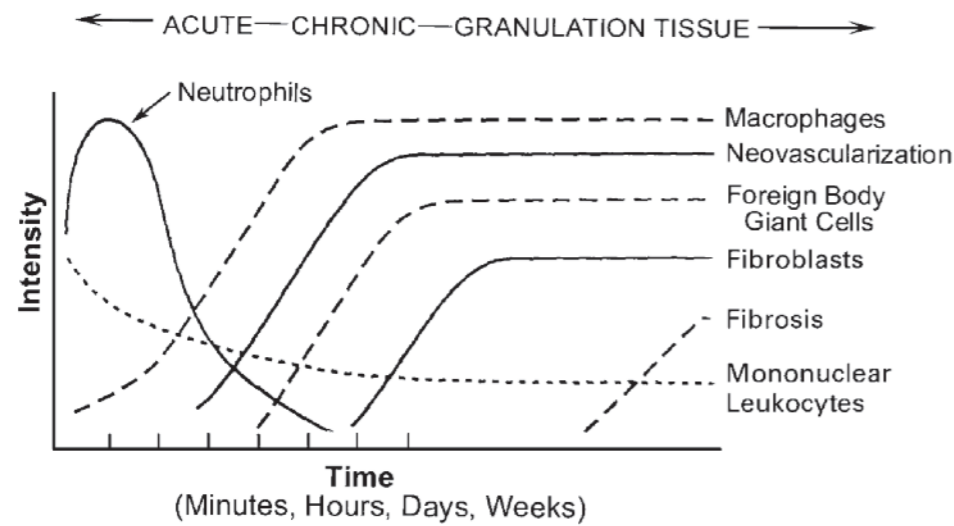


Fig. 2

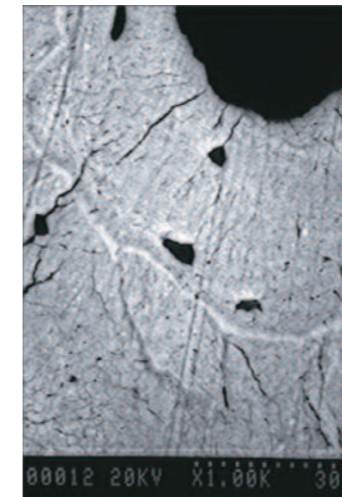


Fig. 3a




Fig. 3b

Fig. 1.

The hierarchy of parameters for successful implant therapy. Successful clinical outcomes rely on proper treatment planning and surgical technique, which provide an essential foundation for success. The overall implant design, shape, size, and screw thread geometry will have major effects on both early and long-term biomechanics. Surface microtopography has been shown to dramatically influence the early stages of peri-implant bone healing and to be particularly important for contact osteogenesis. Refinement of the surface nanotopography can further accelerate contact osteogenesis and also result in bone/implant bonding.

Fig. 2.

The cellular cascade associated with generalized wound healing. Neutrophils are the first leukocytes to migrate into the wound site, followed by macrophages. Neovascularization not only brings these cells and a nutrient supply into the site, but also pericytes, or perivascular cells, which are tissue-resident mesenchymal stem cells that can differentiate into the connective tissue lineages, depending on local environmental cues. In the soft-tissue example illustrated, these cells differentiate into fibroblasts, but in an endosseous site, osteogenic cells would enter the wound site. Reproduced from Anderson JM. The Cellular Cascades of Wound Healing. In: Davies JM (ed). Bone Engineering, Toronto: em2 Inc., 2000:81-93.

Figs. 3a-b.

(A) An SEM photomicrograph of the cement line, which forms a distinct anatomical boundary between new and old bone at remodeling sites. (B) The stages of *de novo* bone formation, including the cement line (Davies 1998).

The Basis of Immediate Loading: Implant Stabilization

Successful immediate loading depends upon three main strategies: (1) achieving primary stability and avoiding implant micromotion in the early stages of healing, (2) achieving secondary (biological) stability as a result of osteogenesis in the peri-implant area, and (3) controlling bone resorption caused by deleterious loading forces that lead to implant instability during healing.⁵

Primary stability is one of the most critical factors.⁶ It must be obtained at the time of the implant's insertion, before any load is applied. Primary stability involves securing the implant within the host bone with sufficient rigidity to preclude any significant micromotion.⁷ The lack of primary stability contributes to fibrous encapsulation of the implant, which represents one of the main factors of implant failure.^{6,8}

The degree of primary stability of endosseous dental implants is believed mainly to depend upon bone type, implant design, patient characteristics, and surgical technique.⁹

After several weeks of healing, primary stability is followed by a biological, or secondary, stability.¹⁰ Biological stability is achieved by contact osteogenesis, the direct deposition of bone tissue on the implant surface. This is

the product of a complex cascade of events that characterize early peri-implant healing, in which osteoconduction and *de novo* bone formation are the key mechanisms.¹¹

The cascade starts at the instant of injury with an acute inflammatory response that lasts from two to five days. Within nanoseconds after implant placement, ionic exchange between the plasma of the extravasated blood




Fig. 3c




Fig. 3d




Fig. 3e




Fig. 3f




Fig. 4a




Fig. 4b




Fig. 5

Figs. 3c-f.

SEM photomicrographs showing the earliest stages of *de novo* bone formation *in vitro* [Courtesy of James Ko, Bone Interface Group, University of Toronto] (c & d). Globular, mineralized, non-collagenous matrix composed mainly of osteopontin, bone sialoprotein, and two proteoglycans (e & f). Further stages of bone matrix deposition, in which a collagenous extracellular matrix has been elaborated, by mature osteoblasts and assembled as fibers on the cement-line matrix.

Figs. 4a-b.

Field emission scanning electron microscopy (FE-SEM) of cpTi DAE (a) and cpTi DAE-DCD (b) implant surfaces. Both surfaces present identical microtopographies due to the initial dual acid etch treatment, but the latter surface has discrete nanocrystals of calcium phosphate (20-100nm in size), which enhance the surface complexity at a nanometer-scale level. Such features can only be observed at very high magnifications but have been shown to have profound biological effects.

Fig. 5.

Photograph of a retrieved DAE-DCD custom-made rectangular implant (4mm x 2.5mm x 1.4mm). This implant was placed in the distal aspect of the rat femur for nine days and subjected to mechanical (tensile) testing. After sample disruption, interfacial bone bonding was observed (see enlargement) as a result of the mechanical interlock between the bone matrix and the DCD nanofeatures.

and the implant surface occurs. Competitive plasma protein adsorption to the implant surface follows within milliseconds and initial cell contact within seconds. Since the majority of cells in blood are red blood cells and platelets, it is these cells that contact the implant surface first, with leukocytes (particularly neutrophils and macrophages) following soon afterwards (Fig. 2). Platelets, once activated, play a crucial role in peri-implant healing.

As tissue healing progresses, coagulating blood not only serves as a reservoir of growth factors but also as a provisional scaffold in which osteogenic mesenchymal cells can migrate. In this context, implant surface topography is of utmost importance for maintaining the blood-clot structure. Microtopographically complex implant surfaces have peaks and valleys that foster increased fibrin adhesion and a higher resistance to

detachment. A strong mechanical interlock to the implant surface stabilizes the fibrin clot during osteogenic cell migration and guarantees that these cells will reach the implant for subsequent bone deposition directly on its surface (see animations at www.ecf.utoronto.ca/~bonehead/).

Formation of granulation tissue starts approximately on the fourth day after implant placement and may last until

the third week post-injury. During this period, osteogenic cells are stimulated and bone deposition commences. In the immediate loading scenario, the rupture of the fibrin clot and vascular network due to excessive micromovement of the implant body will negatively affect osteogenesis. The tolerable level of implant micromotion under immediate loading during healing has been reported to range from 50 to 150µm.⁸

John E. Davies, BDS, PhD, DSc (continued)

Once migrating osteogenic cells reach the implant surface, they start secreting the first organic matrix, devoid of collagen and composed of osteopontin, bone sialoprotein, and proteoglycans. This first layer, analogous to the cement line formed during normal bone remodeling (Figs. 3a-b), provides nucleation sites for calcium phosphate, which subsequently grow within the organic matrix. After the deposition of the cement-line matrix, the osteogenic cells differentiate into osteoblasts that elaborate the collagenous extracellular matrix assembled as fibers. Finally, the collagenous fibers undergo calcification and are separated from the underlying substratum by a calcified non-collagenous matrix.¹¹ This stage is named *de novo* bone formation (Figs. 3c-f).

Osteogenesis in a peri-implant environment results from two distinct mechanisms. *Distance* osteogenesis occurs when bone matrix is deposited from the host bone towards the implant surface. *Contact* osteogenesis occurs when bone matrix is deposited from the implant surface to the host bone (see animations at www.ecf.utoronto.ca/~bonehead/). The anatomical location and surface topographical design of the implant influence both phenomena. However, while osteoconduction is influenced by and dependent upon the implant surface, the process of bone formation itself is independent of the surface material. This explains why bone has been shown to form on almost any non-toxic surface from Teflon™ to titanium alloy. Bone grows both appositionally and through a matrix; the former process is slower (0.6-1µm/day) than the latter (30-50µm/day).¹² However, when osteoconduction results in bone growth along a material surface, there is the possibility that the bone may bond to the implant surface, a phenomenon known as bone bonding.

Three theories of bone bonding have emerged in the literature: the “physico-chemical” (often abbreviated to “chemical”), the “micro-mechanical,” and the “biochemical.” Speculation that a variety of chemical interactions drove the Bone Bonding® Process was first advanced by Hench et al in 1971.¹³ While the authors undertook no experiments to address their speculations, this paper enormously influenced the subsequent literature. The chemical theory was adopted by Jarcho,¹⁴ and a similar approach was employed by Tracy and Doremus¹⁵ and Bonfield and Luklinska.¹⁶ This focus on

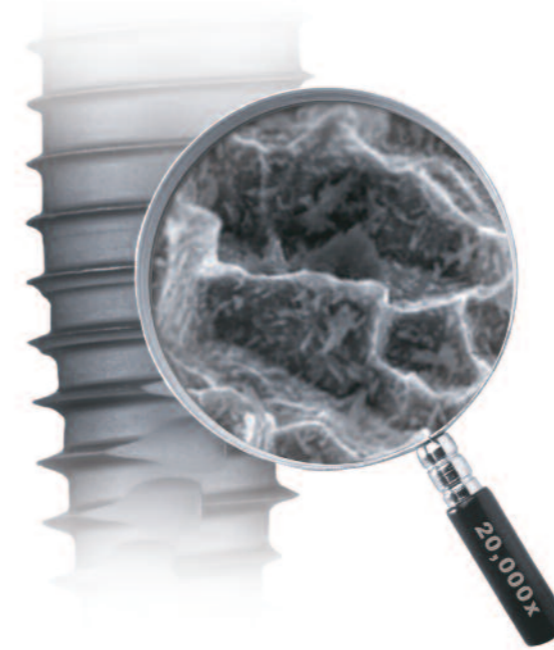chemistry has also been adopted by the most recent so-called “biochemical” theory of bone bonding. However, the latter is neither based upon experiment nor any biochemistry; it is solely a speculation on the importance of small atomic percentages of dopant ions in metal-oxide surfaces without any consideration of very significant differences in microtopography of the materials examined.¹⁷ Of the three theories of the mechanism of bone bonding, only one is based on robust experimental evidence. The “micro-mechanical” theory has evolved from an understanding of how new bone bonds to old bone in the natural process of bone remodeling, and has been substantiated by evidence from both *in vitro* and *in vivo* experimentation.¹⁸

Implant Surface Design

The first generation of endosseous root-form implants introduced by Brånemark was characterized by a relatively smooth surface obtained by machining titanium. Subsequently, various techniques were developed to modify the implant surface topography, using both additive and subtractive processes. The additive approach typically employs deposition methods such as titanium or hydroxyapatite plasma spraying. The subtractive approach uses techniques such as sandblasting or acid etching.

As discussed above, the characteristics of the implant surface play a major role in the early events of endosseous healing and contribute to improved secondary implant stability. *In vivo* studies employing implants with a complex surface topography have shown increased shear strength and removal resistance after healing. A higher percentage of bone-implant contact (BIC) has been demonstrated on implants with microtopographically complex surface designs in comparison to those of originally smoother surfaces.¹⁹

Recent research has focused on understanding the role of implant surface nanotopography on the mechanisms of peri-implant healing.²⁰ By definition, nanotopographic features range in size between 1-100nm. Changes to the implant surface topographic design at the nanometer level have been shown to affect tissue response positively during healing and consequently enhance osteogenesis.^{21,22} Various technologies have been developed to create nanotopographical features on endosseous implant surfaces with successful experimental outcomes.²² One such



approach involves the discrete crystalline deposition (DCD) of calcium phosphate (CAP) (20-100nm) on the titanium surface by means of a sol-gel process.²³ The resulting nanocrystals cover an area of about 50-60% of the implant surface and enhance its complexity on a nanometer scale without altering its original microtopography (Fig. 4). The CAP nanoparticles have been shown to adhere strongly to the surface of DAE commercially pure titanium (cpTi) and titanium alloy (Ti6Al4V) implants, and the ability of the nanotopographically complex DCD implant surface to enhance early healing (osteoconduction) has been evaluated using bone-ingrowth chambers fabricated of either cpTi or Ti6Al4V. The internal walls of the chambers were treated by the DAE or DAE-DCD method and implanted in rat femora. Harvested samples were resin-embedded in blocks, which were ground and backscatter-electron-imaged (BSEI) numerous times at different planes of the chamber height. BIC was measured from 1087 micrographs. The results showed that the DCD nanotopography enhanced osteoconduction significantly on both cpTi and Ti6Al4V implant surfaces.²¹

The question of whether the DCD nanofeatures render metallic surfaces a Bone Bonding® Surface (i.e. NanoTite™ Implant Surface, BIOMET 3i) has also been investigated. The bone bonding phenomenon is characterized by a strong micromechanical interlock between the bone matrix and the implant surface. When DAE and DAE-DCD cpTi and

Ti6Al4V implants implanted in rat femora were subjected to a disruption test in an Instron machine, the results revealed that the DCD treatment rendered all metallic implant surfaces bone bonding (Fig. 5), and significantly higher force values were required to disrupt them.²³

Clinical studies employing implants with the DAE-DCD surface have also been conducted.^{24,25} When custom-made test implants (2 x 9.5mm) of either DAE or DAE-DCD surfaces were inserted in the posterior maxillae of patients for four and eight weeks, in a double-blind randomized trial, the results showed significantly greater percentages of BIC around DCD-treated implants in comparison to DAE implants.²⁴ Histological findings at four weeks showed predominant signs of contact osteogenesis for DCD groups, whereas distance osteogenesis was observed in the DAE groups.

A recent prospective, multicenter clinical trial has been published with one-year follow-up of DCD implants placed under an immediate loading protocol.²⁵ The cases were selected for rehabilitation of fixed partial prostheses and single-tooth restorations (STR), which are considered as clinical challenges for this type of approach. Following surgical placement of the implants, the prostheses were inserted within 48 hours. A total of 335 implants were provisionalized (128 STR and 88 multiple-unit fixed prostheses) under the same protocol, which was followed by the participating 15 study centers located worldwide. This one-year interim report showed a cumulative survival rate of 94.4%, which the authors consider as good performance in comparison to other studies employing different implant topographical designs under stricter inclusion criteria.

Clinical Relevance

Primary stability of the implant is critical for successful osseointegration. While employment of the most refined nano-scale implant surfaces can only be founded on sound treatment planning and expert surgical technique in placing implants that have appropriate three-dimensional forms and microtopography, within this strict clinical framework, peri-implant osteogenesis can be enhanced by implant surface topographical design. Implants with nanotopographically complex surface designs are emerging as the next generation of endosseous dental implants.

References

- Quirynen M, Naert I, van Steenberghe D. Fixture design and overload influence marginal bone loss and fixture success in the Brånemark system. *Clin Oral Implants Res* 1992;3:104-111.
- Brunski JB, Moccia Jr AF, Pollack SR et al. The influence of functional use of endosseous dental implants on the tissue-implant interface. I. Histological aspects. *J Dent Res* 1979;58:1953-1969.
- Romanos GE, Testori T, Degidi M et al. Histologic and histomorphometric findings from retrieved, immediately occlusally loaded implants in humans. *J Periodontol* 2006;76:1823-1832.
- Chiapasco M, Abati S, Romeo E et al. Implant-retained mandibular overdentures with Brånemark System MKII implants: A prospective comparative study between delayed and immediate loading. *Int J Oral Maxillofac Implants* 2001;16:537-546.
- Cooper LF, De Kok JJ, Rojas-Vizcaya F et al. The immediate loading of dental implants. *Compend Contin Educ Dent* 2007;28:216-225.
- Lioubavina-Hack N, Lang NP, Karring T. Significance of primary stability for osseointegration of dental implants. *Clin Oral Implants Res* 2006;17:244-250.
- Sullivan DY, Sherwood RL, Collins TA et al. The reverse-torque test: A clinical report. *Int J Oral Maxillofac Implants* 1996;11:179-185.
- Szmukler-Moncler S, Salama H, Reingewirtz Y et al. Timing of loading and effect of micromotion on bone-dental implant interface: Review of experimental literature. *J Biomed Mater Res* 1998;43:192-203.
- Meyer U, Joos U, Mythili J et al. Ultrastructural characterization of the implant/bone interface of immediately loaded dental implants. *Biomaterials* 2004;25:1959-1967.
- Raghavendra S, Wood MC, Taylor TD. Early wound healing around endosseous implants: A review of the literature. *Int J Oral Maxillofac Implants* 2005;20:425-431.
- Davies JE. Understanding peri-implant endosseous healing. *J Dent Educ* 2003;67:932-949. [Available in color at <http://www.ecf.utoronto.ca/~bonehead>]
- Davies JE, Hosseini MM. Histodynamics of endosseous wound healing. In: Davies JE (ed). *Bone Engineering*. Toronto: em2 Inc., 2000:1-14.
- Hench LL, Splinter RJ, Allen WC et al. Bonding mechanisms at the interface of ceramic prosthetic materials. *J Biomed Mater Res* 1979;5:117-141.
- Jarcho M. Calcium phosphate ceramics as hard tissue prosthetics. *Clin Orthop Relat Res* 1981;157:259-278.
- Tracy BM, Doremus RH. Direct electron microscopy studies of the bone-hydroxyapatite interface. *J Biomed Mater Res* 1984;18:719-726.
- Bonfield W, Luklinska ZB. High resolution electron microscopy of a bone implant interface. In: Davies JE (ed). *The Bone-biomaterial Interface*. Toronto: University of Toronto Press, 1991:89-94.
- Sul Y-T, Johansson P, Chang B-S et al. Bone tissue responses to Mg-incorporated oxidized implants and machine-turned implants in the rabbit femur. *J Appl Biomater & Biomech* 2005;3:18-28.
- Davies JE. Bone Bonding at natural and biomaterial surfaces. *Biomaterials* 2007;28:5058-5067.
- Buser D, Schenk RK, Steinemann S et al. Influence of surface characteristics on bone integration of titanium implants. A histomorphometric study in miniature pigs. *J Biomed Mater Res* 1991;25:889-902.
- Mendonça G, Mendonça DBS, Aragão FJL et al. Advancing dental implant surface technology: from micro- to nanotopography. *Biomaterials* 2008;29:3822-3835.
- Mendes VC, Moineddin R, Davies JE. Discrete calcium phosphate nanocrystalline deposition enhances osteoconduction on titanium-based implant surfaces. *J Biomed Mater Res* 2009; 90A:577-585.
- Davies JE, Schüpbach P, Cooper L. The implant surface and biological response: The changing interface. In: Jostad A (ed). *Osseointegration and Dental Implants*. Ames: Wiley-Blackwell, 2009:213-223.
- Mendes VC, Moineddin R, Davies JE. The effect of discrete calcium phosphate nanocrystals on Bone Bonding to titanium surfaces. *Biomaterials* 2007;28:4748-4755.
- Goené RJ, Testori T, Trisi P. Influence of a nanometer-scale surface enhancement on the novo bone formation on titanium implants: a histomorphometric study in human maxillae. *Int J Periodontics Restorative Dent* 2007;27:211-219.
- Östman PO, Hupalo M, del Castillo R et al. Immediate provisionalization of Nanotite™ Implants in support of single-tooth and unilateral restorations: one-year interim report of a prospective, multicenter study. *Clin Implant Dent Relat Res* 2009, May 7. Epub ahead of print.

*Bone Bonding® is the interlocking of the newly formed cement-line matrix of bone with the implant surface.

Acknowledgments

The author would like to thank his colleagues at the University of Toronto, Drs. Vanessa Mendes and Michel Araújo, for their work in developing the concepts presented in this article.

Adapted with permission from Davies JE, Araújo M, del Fabbro M, Mendes VC, Testori T. The role of implant surface on biological loading. In: Testori T, Galli F, del Fabbro M (eds). *Immediate Loading. The New Age of Implantology*. Chicago: Quintessence. In press.

John E. Davies, BDS, PhD, DSc

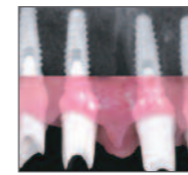

Dr. Davies received his Doctor of Science degree from the University of London and is Professor of Dentistry and Biomaterials at the University of Toronto, Toronto, Ontario, Canada, specializing in research on peri-implant bone healing, bone-tissue engineering, and mesenchymal stem-cell biology. He is also a member of the Institute of Biomaterials and Biomedical Engineering, with cross appointments in the Faculty of Applied Science and Engineering and the Faculty of Medicine at the University of Toronto.

Stability

Clinical factors related to implant stability with tapered implants

Tiziano Testori, DDS, MD, FICD



Immediate occlusal loading of dental implants offers benefits to both patients and clinicians. Although excellent results have been reported for both early and immediately loaded implants, these protocols are technique sensitive. Success depends upon many factors, including the achievement of high primary implant stability. This article reviews some recent studies relating to initial implant stability and presents a protocol to obtain high primary stability for immediately loaded implants. A clinical case illustrating the protocol is presented.

Key Words: primary stability, immediate loading, tapered implants, implant stability

Introduction

Many factors explain the growing popularity of immediate loading protocols. Patients appreciate being able to shorten the overall length of implant treatment and reduce the number of procedures they must undergo in order to obtain fixed implant prostheses. Full-arch immediate loading enables patients to function with non-removable implant prostheses within one to two days of tooth extraction, eliminating the need to experience any period of edentulism with complete dentures. For the implant team, immediate occlusal loading offers multiple benefits including greater cost-effectiveness, fewer post-operative patient visits,¹ and higher referral rates for surgeons.

The original Brånemark protocol called for relatively long (three to six months) unloaded healing intervals because it was thought that placing occlusal loads onto implants

prior to osseointegration could lead to fibrous tissue encapsulation rather than direct bone apposition.²⁻³ Support for lengthy unloaded post-surgical periods also was bolstered by the belief that necrotic bone in implant osteotomies needed to be replaced by new bone before any loads could be tolerated.⁴

In 1979 Ledermann published results associated with successful healing for immediately loaded endosseous implants;⁵ multiple researchers and clinicians subsequently reported similar results.⁶⁻¹³ In 2007, a systematic Cochrane review of 11 randomized controlled trials that compared outcomes for early or immediately loaded implants to outcomes for conventionally loaded implants found no statistically significant differences for any of the meta-analyses.¹⁴ Histomorphometric analyses of retrieved, immediately loaded endosseous implants have

Tiziano Testori, DDS, MD, FICD (continued)

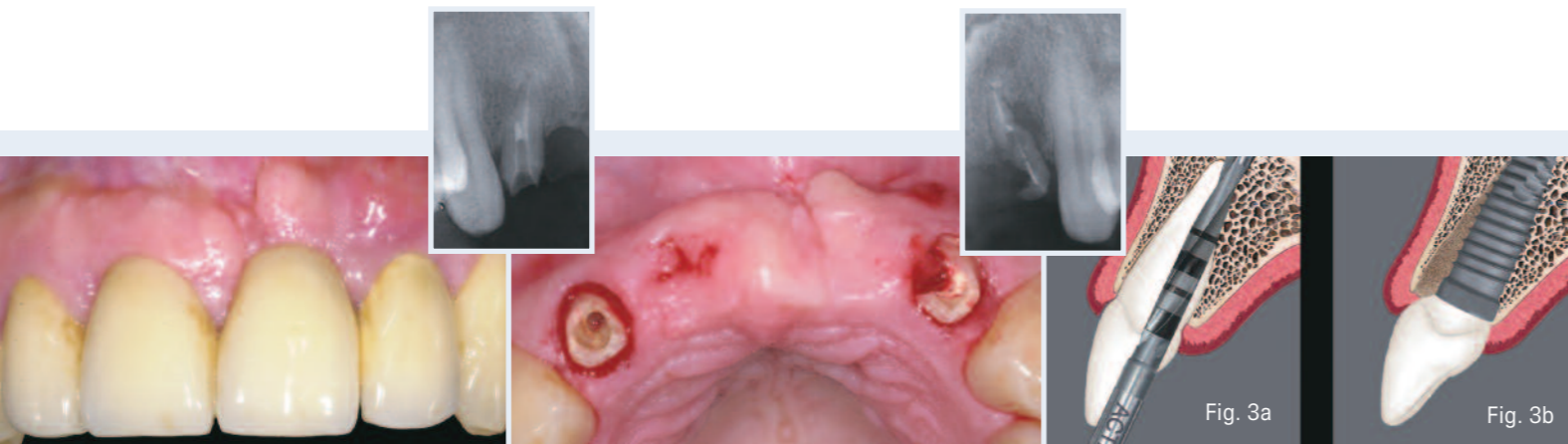


Fig. 1 Pre-operative clinical photograph.

Fig. 2 After removal of the patient's failing FPD, periapical radiographs (inset) revealed that both lateral incisors were fractured and unsalvageable.

Fig. 3a A 2mm diameter twist drill was positioned against the palatal wall of the pre-existing socket.
Fig. 3b Illustration of a properly positioned tapered implant within the prepared osteotomy/socket.

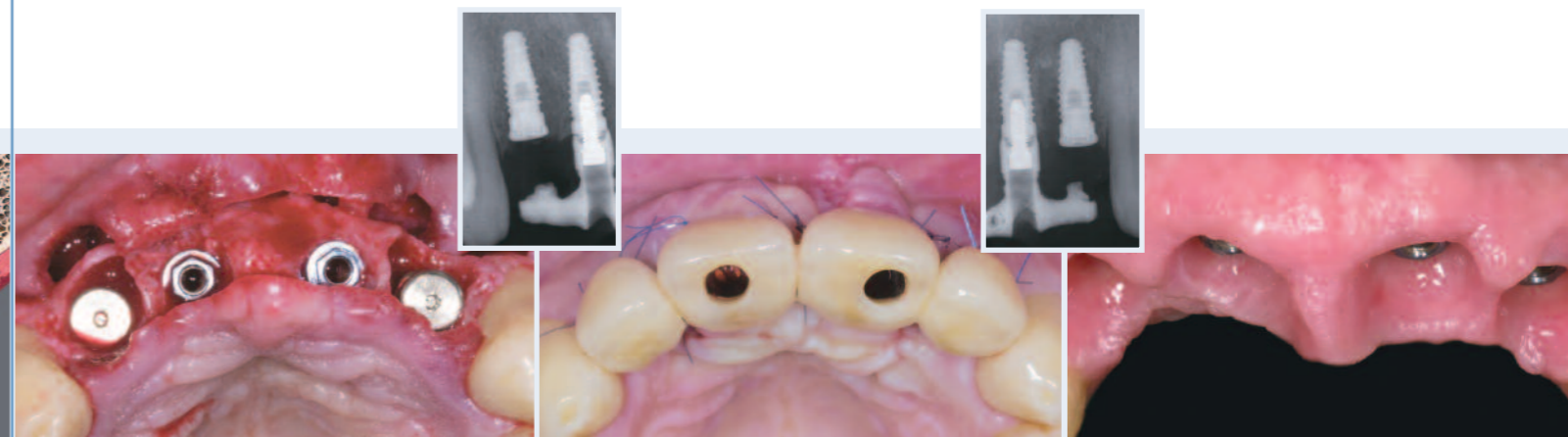

Fig. 4 Implants were placed in the central and lateral incisor positions.

Fig. 5 Occlusal view of the laboratory-fabricated screw-retained provisional restoration placed one day after implant placement.

Fig. 6 Six months later, the lateral incisor implants were uncovered. Soft-tissue healing occurred, and the patient presented for impressions.

demonstrated that immediate loading does not impede osteogenesis and bone remodeling.¹⁵⁻¹⁸ Peri-implant bone and soft-tissue levels around healed, immediately loaded implants also do not appear to differ from those found around traditionally loaded implants.¹⁹

Despite the broad body of evidence validating the predictability of immediate loading in carefully selected patients, some studies have reported higher failure rates with an immediate-loading approach, as compared to a staged approach for implant placement.^{10,20-22} However, it should be noted that some of these findings related to machine-surfaced implants^{10,20} and others related to single implants.^{21,22} This suggests that immediate loading is technique sensitive and should be applied to patients with caution.

Achieving High Primary Stability

Crucially important to immediate occlusal loading is achieving high primary implant stability. Primary stability must be sufficient to allow implants to resist micromovement until adequate biologic stability has been established.²³ For roughened implant surfaces, research has demonstrated that the tolerable range of micromotion is between 50 and 150 µm.²⁴

A number of recent studies have shed light on various aspects of initial implant stability. In 2009 Rozé et al,²⁵ investigating a possible correlation between bone micro-architecture and primary implant stability, placed 22 implants in human cadaver maxillae and mandibles for which the bone structure had been determined pre-operatively

by computed tomography (CT). Primary implant stability was measured by resonance frequency analysis; Osstell ISQ values ranged from 50 to 70. No correlation was found between the ISQ values and the trabecular bone histomorphometrical parameters. Instead, the authors concluded that primary implant stability is correlated to the cortical thickness around implants, which can be assessed with standard clinical CT scans.

O'Sullivan et al²⁶ compared the primary implant stability of five implants: Nobel Biocare's Standard threaded, Mark II self-tapping, and Mark IV tapered self-tapping implants (Nobel Biocare AB, Gothenburg Sweden), the AstraTioblast (AstraTech AB, Mölndahl, Sweden), and the BIOMET 3i OSSEOTITE® (BIOMET 3i) Implant. Fifty-two implants were placed into maxillary bones of nine unembalmed human cadavers; peak-insertion-torque, resonance-frequency, and removal-torque values were recorded at each implant-placement site. Qualitative assessments of bone quality at each site were also made. The authors found that all implants demonstrated good primary stability in Type II and III bone, but the Standard, Mark II, OSSEOTITE, and Tioblast implants were less stable when placed into Type IV bone. The authors concluded that tapered implants exhibited higher insertion torques than cylindrical implants, as well as significantly higher resonance-frequency values, which indicated a higher interfacial stiffness at the implant-bone interface.

Turkyilmaz et al,²⁷ using smaller-diameter drills to enhance primary implant stability, placed 60 implants into the posterior maxillae of 22 patients and recorded bone

densities (as determined with computerized tomography), maximum insertion torque, and resonance-frequency-analysis results. Strong correlations were observed between bone density, insertion torque, and implant stability values at implant placement. The authors concluded that using smaller diameter drills for implant placement in posterior maxillae, where bone quality is generally poor, may improve primary implant stability.

Ottoni et al²⁸ placed 46 Frialit-2 implants into 23 patients and restored these within a 24-hour period with provisional crowns designed to receive occlusal masticatory loads. A minimum insertion torque of 20Ncm was achieved. This approach was compared to a control group of implants restored after a healing period. After a 24-month data-collection period, the experimental group included 10 failed implants, nine of which had been placed with an insertion torque of 20Ncm. Only one implant from the control group failed during the same period. The survival rate was independent of implant length, site position, and bone quality and quantity. Relative risk for implant failure was associated with insertion torque in the experimental group but was not significant for the control group. To achieve osseointegration, it was found that an insertion torque above 32Ncm was necessary. The authors' low insertion torque (20Ncm) was associated with increased potential for loss, which could be decreased by 20% per every additional 9.8Ncm of insertion torque.

In 2009, Neugebauer et al²⁹ investigated seven different surgical motors, measuring torque during typical surgical and

prosthetic procedures using a special load-transfer mechanism for a torque gauge. For each setting, 30 measurements were made and means were calculated. The authors concluded that the highest percentage shortfall was 20.5% at a set torque of 11.4Ncm (absolute deviation, 2.4Ncm). The highest percentage by which a torque was exceeded was 54.6% (absolute deviation, 5.5Ncm). The lowest value for absolute shortfall was found to be -5.6Ncm at a set torque of 45Ncm. The highest absolute value exceeded was 15Ncm at a set torque of 40Ncm. Potentially problematic torque values were identified in the low-torque-value setting, as the implant position may be changed if a drilling unit applies excessive torque to a healing abutment or cover screw. In addition, torque values above the critical value of 50Ncm may be applied unwittingly while working with a set torque of 40Ncm. The authors concluded that although surgical motors for implant treatment demonstrated acceptable torque measurements for implant procedures, annual or chairside calibration with a standard handpiece is recommended in order to apply consistent quantities of torque and reduce implant failure rates.

Trisi et al³⁰ in 2009 designed a study to determine whether micromotion at the implant/bone interface was related to primary implant stability achieved with increasing insertion-torque values. A total of 120 Ti-Bone implants were placed into three categories of fresh bovine bone samples: hard, normal, and soft. Five groups of peak insertion torque values (20, 35, 45, 70 and 100Ncm) were evaluated in each bone-density category. A loading device consisting of a digital force

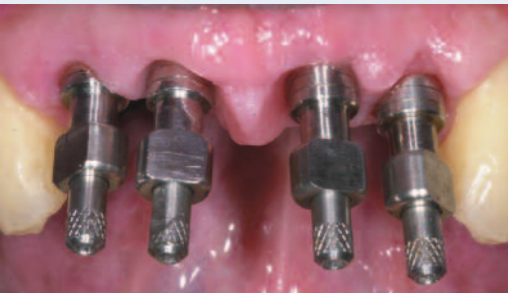

Fig. 7
Eight weeks after uncovering, implant pick-up impression copings were placed onto the implants.

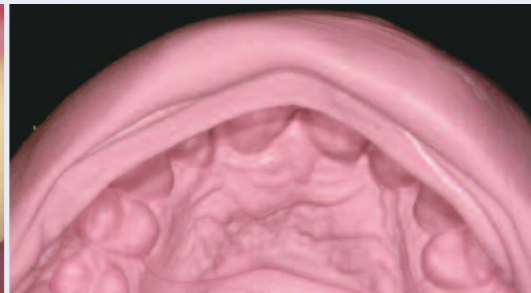


Fig. 8
A silicone mold of the provisional restoration was used to create the second provisional restoration as well as the definitive restorations.

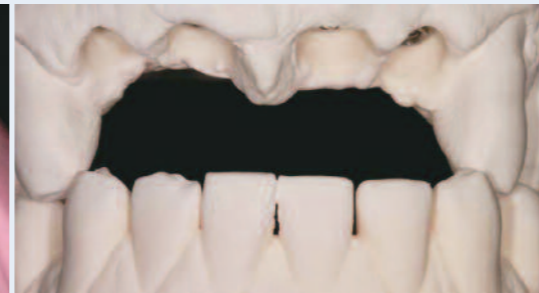

Fig. 9
Anterior view of the mounted master casts.

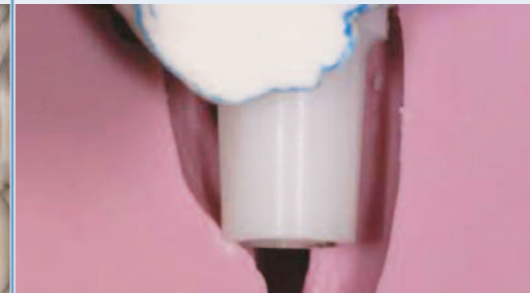

Fig. 10a
The silicone mold was fitted onto the land area of the cast (over the ZiReal® Posts). This identified the amount of reduction needed.

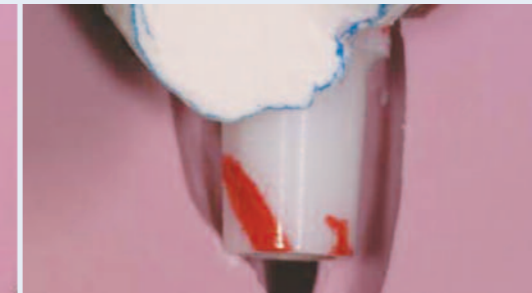

Fig. 10b
A red marking pen was used to indicate the locations of the planned reductions on the abutment.

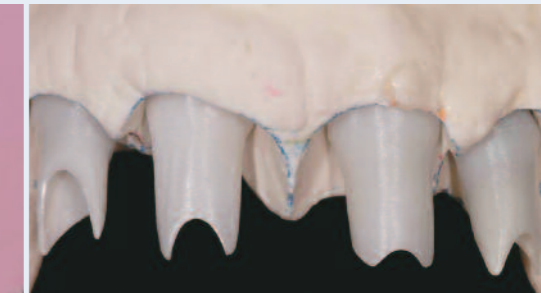

Fig. 11
The prepared abutments in place on the master cast. These were prepared consistent with the contours of the provisional restoration.

gauge and a digital micrometer was used to measure the implants' micromovement during the application of 20, 25, and 30Ncm lateral forces. The authors found a statistically significant difference between implant micro-mobility placed with different levels of torque and in different bone densities. In soft bone, it was not possible to achieve more than 35Ncm of peak insertion torque. The authors concluded that increasing peak insertion-torque values reduced implant micromotion within the osteotomies. In addition, micromotion in soft bone was found to be consistently high, which could lead to failures relative to osseointegration.

In light of such research and the author's 21 years of clinical experience in implantology and 30 years in practice, the author has developed a protocol for achieving high primary stability for immediately loaded implants.

The protocol includes:

- Identifying the quality and quantity of available bone
- Using an implant with optimal macro- and micro-geometry
- Paying attention to biology and biomechanics
- Undersizing osteotomies and preparing these precisely for placement of tapered implants
- Matching the drilling sequence to the bone type
- Understanding the surgical instrumentation
- Understanding the instruments available for determining primary stability at the time of implant placement
- Performing the surgical procedure accurately; paying attention to details

Additionally, the author considers two-handed guidance of the handpiece to be critical for successful implant osteotomy preparation and implant placement in difficult cases. One hand should be maintained on the head of the handpiece and significant apical force should be used to maintain control of the drills. The angulation of the handpiece and drill should be monitored continually during both guided and non-guided surgeries. The author always uses a bone tap in dense bone prior to placing an implant into an osteotomy.

Clinical Case Presentation

The following case illustrates an application of this protocol. The patient, a 35-year-old male, presented with a failing maxillary anterior fixed partial denture that had replaced his central incisors in the wake of their traumatic evulsion (Fig. 1). Clinical examination of the two lateral incisors, which supported the prosthesis, found that the right one had a vertical root fracture, while the left one had suffered a major endodontic failure (Fig. 2). Intraoral radiographs (insets) and a CT scan of the edentulous ridge revealed that the bone quality was Type II, and the vertical and buccolingual dimensions were adequate to accommodate placement of implants. Moreover, approximately 33mm of intercuspid prosthetic space was available – more than enough to allow for an optimal inter-implant distance.

The patient provided informed consent for a treatment plan that called for immediate loading of two implants to be placed in the central incisor positions and delayed loading for two implants placed in the lateral incisor positions.

Impressions were made, and a wax-up was obtained for fabrication of a fixed provisional restoration and a surgical template.

The two lateral incisors were atraumatically extracted, and a full-thickness mucoperiosteal flap was elevated. Osteotomies were created in the positions indicated by the surgical guide. At the two extraction sites, instead of following the long axis of each socket, the bur was positioned against the palatal wall and aligned with the cingulum of the future restoration. Following these directions, the initial osteotomy began 5mm to 7mm more apically from the soft-tissue contour on the palatal side (Figs. 3a and 3b).

Four 4.0mm x 11.5mm OSSEOTITE® Natural Tapered Implants (BIOMET 3i) were placed, and cover screws were placed on the two lateral implants (Fig. 4). Positioning the two lateral incisor implants into the bone on the palatal wall of the extraction sites resulted in a small gap between each implant and the labial plate. In order to establish a thicker, more stable labial wall that would better resist bone resorption, the gaps were filled with autogenous bone collected from the flutes of the shaping drills.

Transfer assemblies were connected to the two central incisor implants. After temporarily suturing the flap, an impression was made. The sutures were then removed around the two central incisor implants, and a bone dehiscence on the buccal plate of the right implant was grafted. A resorbable collagen membrane was placed on

that implant, and a connective tissue graft harvested from the palatal area was also used to cover the expanded buccal contours.

To prevent collapse of the soft tissue until delivery of the provisional prosthesis the following day, wide healing abutments were placed on the two central incisor implants and tightened to 10Ncm. These were removed the next day, and a metal-reinforced provisional restoration with cantilevered lateral incisors was screw-retained to the two central incisor implants and checked to ensure the absence of centric and eccentric contacts (Fig. 5). The patient was instructed not to masticate on the provisional restoration for at least eight weeks.

Six months later, the two lateral incisor implants were exposed in a flapless procedure. Measurement of the implant-stability quotient by resonance frequency analysis confirmed secondary osseointegration of all four implants. After a gingivoplastic procedure was carried out to smooth the soft-tissue contours, the provisional restoration was re-connected to the two central incisor implants.

The soft tissue was allowed to heal for an additional eight weeks, and then the patient presented for implant-level impressions (Fig. 6). The soft-tissue contours were established by the contours established in the provisional restoration. Implant-level impressions were made (Fig. 7); the diagnostic cast of the provisional restoration was to be used as a reference in fabricating the definitive restoration (Fig. 8). A master cast was created and mounted in the

Tiziano Testori, DDS, MD, FICD (continued)

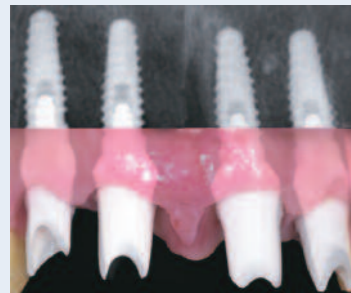

Fig. 12
Composite image of the prepared ZiReal® Posts in place on the implants. Note that the margins of the abutments were subgingival.

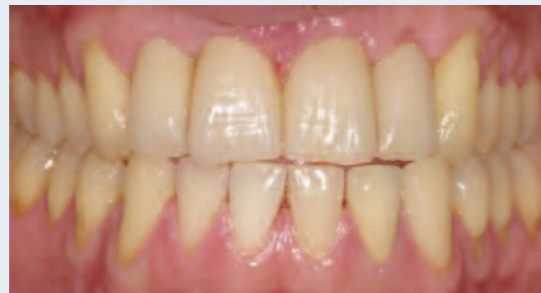

Fig. 13
Clinical photograph of the definitive restorations in place.

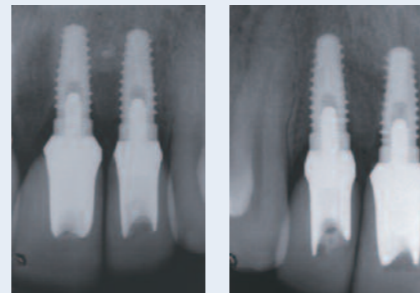


Fig. 14
Post-restorative periapical radiographs show minimal bone remodeling around the implants, more than one year after placement.

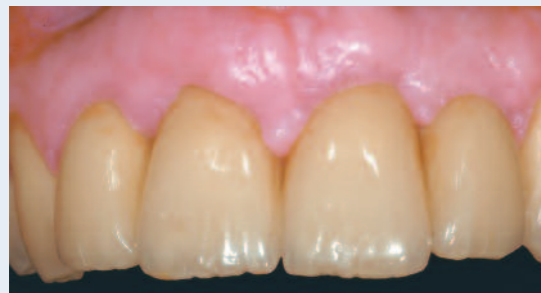

Fig. 15
Clinical photograph of the definitive restoration after more than eight years follow-up. Note the stability of the peri-implant soft tissues.

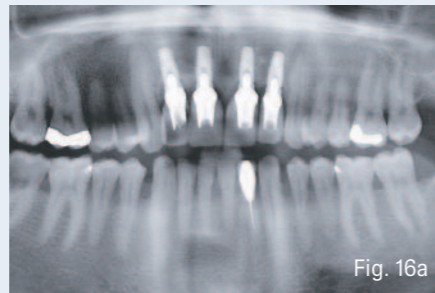


Fig. 16a-b-c
Orthopantomograph and periapical radiographs eight years and five months post loading (implant placement January 2002) of the peri-implant soft tissues.

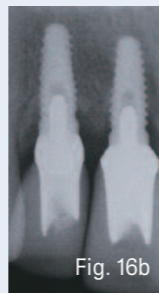


Fig. 16b

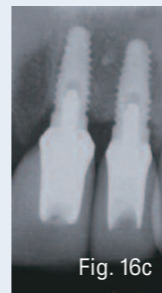


Fig. 16c

correct jaw relationship (Fig. 9). Teeth were waxed, and ZiReal® Posts (BIOMET 3i) were placed onto the master cast (Figs. 10a and b) and modified to conform to the shape of the desired restoration emergence profiles (Fig. 11). The prepared modified posts were placed onto the implants and secured with retaining screws tightened to 32Ncm (Fig. 12), and the provisional restoration was cemented to the posts. Six months later, after maturation of the soft tissues, the second provisional restoration was removed, and four definitive all-ceramic crowns (IPS Empress 2, Ivoclar Vivadent, Amherst, New York, USA) were cemented in place (Fig. 13). Periapical radiographs taken during this visit, more than a year after implant placement, showed minimal peri-implant bone remodeling (Fig. 14).

After more than eight years of follow-up, the peri-implant soft tissues and the bone levels remain stable (Figs. 15 and 16a-c).

Clinical Relevance

Among the conditions necessary to enable successful immediate occlusal loading, one of the most crucial is high primary stability for newly placed implants. Adherence to the following recommendations is suggested:

- Identify the quality and quantity of available bone for each implant site.
- Use an implant with optimal macro- and micro-geometry.
- Pay attention to biology and biomechanics.
- Undersize osteotomies and prepare these precisely for placement of tapered implants.
- Match the drilling sequence to the bone type.
- Understand the surgical instrumentation.
- Understand the instruments available for determining primary stability at the time of implant placement.
- Perform the surgical procedure accurately; pay attention to details.

References

1. Chee W, Jivraj S. Efficiency of immediately loaded mandibular full-arch implant restorations. *Clin Oral Impl Dent* 2003;5:52-56.
2. Albrektsson T, Brånemark P-I, Hansson HA et al. Osseointegrated titanium implants: Requirements for ensuring a long-lasting direct bone to implant anchorage in man. *Acta Orthop Scand* 1981;52:155-170.
3. Albrektsson T, Hansson HA, Lekholm U. Osseointegrated dental implants. *Dent Clin North Am* 1986;30:151-174.
4. Brånemark P-I, Hansson BO, Adell R et al. Osseointegrated implants in the treatment of the edentulous jaw. Experience from a 10-year period. *Scand J Plast Reconstr Surg Suppl* 1977;16:1-132.
5. Ledermann PD. Stegprothetische Versorgung des zahnlosen Unterkiefers mit Hilfe plasmabeschichteten Titanschraubimplantaten. *Deutsche Zahnärztliche Zeitung* 1979;34:907-911.
6. Schroeder A, Maeglin B, Sutter F. Das ITI-Hohlzylinderimplantat Typ F zur Prothesenretention beim zahnlosen Kiefer. *Schweizerische Monatschrift für Zahnheilkunde* 1983;93:720-733.
7. Babbush CA, Kent J, Misick D. Titanium plasma-sprayed (TPS) screw implants for the reconstruction of the edentulous mandible. *J Oral Maxillofac Surg* 1986;44:274-282.
8. Schnitman P, Wöhrle PS, Rubenstein JE. Immediate fixed interim prostheses supported by two-stage threaded implants: methodology and results. *J Oral Implantol* 1990;2:96-105.
9. Balshi TJ, Wolfinger GH. Immediate loading of Brånemark implants in edentulous mandibles: a preliminary report. *Implant Dent* 1997;6:83-88.
10. Schnitman P, Wöhrle PS, Rubenstein JE et al. Ten years results for Brånemark implants immediately loaded with fixed prostheses at implant placement. *Int J Oral Maxillofac Implants* 1997;12:495-503.
11. Tarnow DP, Emtiaz S, Classi A. Immediate loading of threaded implants at stage I surgery in edentulous arches: ten consecutive case reports with 1- to 5-year data. *Int J Oral Maxillofac Implants* 1997;12:319-324.
12. Wöhrle PS. Single-tooth replacement in the aesthetic zone with immediate provisionalization: fourteen consecutive case reports. *Pract Periodont Aesthet Dent* 1998;10:1107-1114.
13. Brånemark P-I, Engstrand P, Ohmell L-O et al. Brånemark Novum: A new treatment concept for rehabilitation of the edentulous mandible. Preliminary results from a prospective clinical follow-up study. *Clin Implant Dent Relat Res* 1999;1:2-16.
14. Esposito M, Grusovin MG, Willings M et al. Interventions for replacing missing teeth: different times for loading dental implants. *Cochrane Database Syst Rev* 2007 Apr 18;(2):CD003878.
15. Linkow LI. Retrieved analysis of a blade implant after 231 months of clinical function. *Implant Dent* 1992;1:37-43.
16. Piatelli A, Corigliano M, Scarano A et al. Bone reactions of early occlusal loading of two-stage titanium plasma-sprayed implants: A pilot study in monkeys. *Int J Periodont Restorative Dent* 1997;17:163-169.
17. Piatelli A, Paoloanonio M, Corigliano M et al. Immediate loading of titanium plasma-sprayed screw-shaped implants in man: A clinical and histological report of 2 cases. *J Periodontol* 1997;68:591-597.
18. Testori T, Szmukler-Moncler S, Francetti L et al. Immediate loading of Osseotite implants: A case report and histologic analysis after 4 months of occlusal loading. *Int J Periodontics Restorative Dent* 2001;21:451-459.
19. Galli F, Capell M, Zuffetti F et al. Immediate non-occlusal vs. early loading of dental implants in partially edentulous patients: a multicentre randomized clinical trial. Peri-implant bone and soft-tissue levels. *Clin Oral Impl Res* 2008;19:546-552.
20. Ericsson I, Nilson H, Lindhe J et al. Immediate functional loading of Brånemark single tooth implants. An 18-months' follow-up study. *Clin Oral Impl Res* 2000;11:26-33.
21. Jaffin RA, Kumar A, Berman CL. Immediate loading of implants in partially and fully edentulous jaws: a series of 27 case reports. *J Periodontol* 2000;71:833-838.
22. Chaushu G, Chaushu S, Tzohar A et al. Immediate loading of single-tooth implants: immediate versus non-immediate implantation. A clinical report. *Int J Oral Maxillofac Implants* 2001;16:267-272.
23. Szmukler-Moncler S, Salama H, Ringewirtz Y et al. Timing of loading and effect of micro-motion on bone-implant interface: A review of experimental literature. *J Biomed Mat Res* 1998;43:192-203.
24. Szmukler-Moncler S, Piattelli A, Favero G et al. Considerations preliminary to the application of early and immediate loading protocols in dental implantology. *Clin Oral Impl Res* 2000;11:12-25.
25. Rozé J, Babu S, Saffarzadeh A et al. Correlating implant stability to bone structure. *Clin Oral Implants Res* 2009;20(10):1140-5.
26. O'Sullivan D, Sennerby L, Meredith N. Measurements comparing the initial stability of five designs of dental implants: a human cadaver study. *Clin Implant Dent Relat Res* 2000;2(2):85-92.
27. Turkyilmaz I, Aksoy U, McGlumphy EA. Two alternative surgical techniques for enhancing primary implant stability in the posterior maxilla: a clinical study including bone density, insertion torque, and resonance frequency analysis data. *Clin Implant Dent Relat Res* 2008;10(4):231-237.
28. Ottoni JMP, Oliveira ZFL, Mansini R et al. Correlation between placement torque and survival of single-tooth implants. *Int J Oral Maxillofac Implants* 2005;20:769-776.
29. Neugebauer J, Scheer M, Mischkowski RA et al. Comparison of torque measurements and clinical handling of various surgical motors. *Int J Oral Maxillofac Implants* 2009;24(3):469-476.
30. Trisi P, Perfetti G, Baldoni E et al. Implant micromotion is related to peak insertion torque and bone density. *Clin Oral Implants Res* 2009;20(5):467-471.

Laboratory Colleague: Marco Cossu, MDT, Lugano, Switzerland.

Acknowledgements

We would like to thank the Restorative Colleague Jorg M. Ritzmann, DDS, Milano, Italy, and Anita Daniels and Carl Drago, DDS for editing this paper.

Tiziano Testori, DDS, MD, FICD



Dr. Testori is Assistant Clinical Professor and Head of the Section of Implant Dentistry and Oral Rehabilitation, Department of Odontology, at the University of Milan, I.R.C.C.S., Galeazzi Institute (Chairman Prof. R.L. Weinstein), in Milan, Italy. He has authored numerous publications and a textbook on immediate loading. He maintains a private practice specializing in implant dentistry in Como, Italy. His website is www.implantologiaitalia.it.

Predictable guided bone regeneration



Markus B. Hürzeler, DMD, PhD
Clinical Associate Professor
University of Freiburg
Freiburg, Germany
Private Practice
Munich, Germany

A lot can be done to make guided bone regeneration more predictable. For one thing, getting blood vessels into the regenerated area is extremely important. For instance, augmentations done with block bone grafts are very difficult for blood vessels to grow into. It is easier biologically to use granules, into which the blood vessels can grow, and if granules contain interconnecting pores, that is even better. A pore diameter of about 200 microns appears to be optimal for fostering vascularization and the in-growth of osteoblasts.

The second most important fact from a biological standpoint is graft stability. If the augmentation materials are mobile during the maturation process, mineralization cannot occur.

A related question is whether implants can be placed simultaneously with the augmentation procedure. This depends on the defect size. It is always a question of whether the implant can be primarily stabilized in the defect. If not, implant placement must be delayed for four or five months. But otherwise, I prefer to offer simultaneous treatment because it is better for the patient to only have to undergo a single surgical procedure.

In my practice, our team has also looked for approaches that minimize the risk of membrane exposure. We have encountered fewer complications by using a combination of two different membranes: one on the exterior that integrates well with the tissue, so that the flap can easily attach to it; and a second membrane with a longer barrier function internal to the membrane described above.

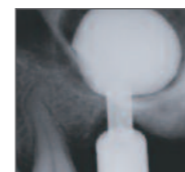
Flap management is also very important. It starts as soon as a full-thickness flap is opened. Cutting into the soft tissue always produces bleeding. If this is done immediately before closing, the result will be more swelling later on. So the first step is to manage the soft tissue immediately after elevation: achieve mobility in the flap to cover the augmented area later. It is also important to use microsurgical instruments and appropriate suture material. Using very small suture material tells the surgeon if the flap design is correct. With 7-0 sutures, if the suture pulls the flap too much, it will tear. If that happens, flap management was inadequate.

Hopefully in the future, a manufacturer will introduce a membrane that combines the two functions that are needed: tissue integration on the outside and extended barrier function underneath. It would be better not to have to use two separate membranes in one surgical procedure. Beyond that, I also expect to see further advances in grafting material. These could include the incorporation of proteins on the surface of the graft material to enhance the osteoconduction, as well as increased osteoinductive capacities. This will help make the final results of guided bone regeneration better and more predictable.

sinus elevation

The use of minimally invasive antral membrane balloon elevation (MIAMBE) to treat the posterior maxilla: A clinical presentation

Ziv Mazor, DMD



Sinus-floor elevation has become a predictable and effective technique for increasing the vertical dimension of atrophic posterior maxillary alveolar bone. However, this approach is time-consuming, costly, can have negative sequelae for patients, and poses the risk of a number of complications. A simple and less invasive version of the osteotome sinus-floor elevation technique has been developed. This procedure is described here, and its application is illustrated with a case presentation.

Key Words: sinus elevation, atrophic posterior maxilla, site preparation, grafting

Introduction

A number of anatomic factors complicate the placement of dental implants in the posterior maxilla. Post-extraction resorption patterns, use of a removable prosthesis, physical trauma, periodontal disease, and/or pneumatization of the maxillary sinus can all significantly decrease the height and width of the residual alveolar ridge.¹ Moreover, bone quality in this region tends to be the least dense in the oral cavity;² typically Type III and IV.

To increase the likelihood of long-term survival of dental implants placed into atrophic posterior maxillae, the use of shorter³ and wider⁴ implants has been recommended. An alternative approach has been to augment deficient ridges.⁵ But problems with graft-material resorption have been reported,⁶ and even when such grafting succeeds, the resultant reduction of the posterior

interocclusal space may make prosthetic restoration difficult.⁷

Augmentation of the sinus floor has thus emerged as another alternative for increasing subantral bone height. First described by Tatum,⁸ subantral augmentation has since evolved. In the modified Caldwell-Luc approach, a hinged window in the lateral wall of the maxilla is created, then gently pressed inward and upward into the sinus cavity, lifting the Schneiderian membrane and creating a new sinus floor. Bone-graft material is then introduced into the void between the elevated tissues and the original sinus floor. Implants may be placed simultaneously or after a healing period. Results from this approach have been so favorable that a 1996 consensus conference organized by the Academy of Osseointegration declared that sinus grafting

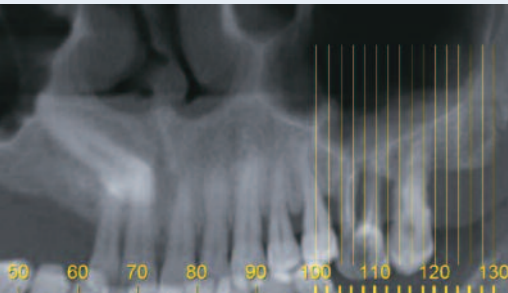


Fig. 1
A CT scan revealed that the subantral bone height was 2mm and the width was 10mm.

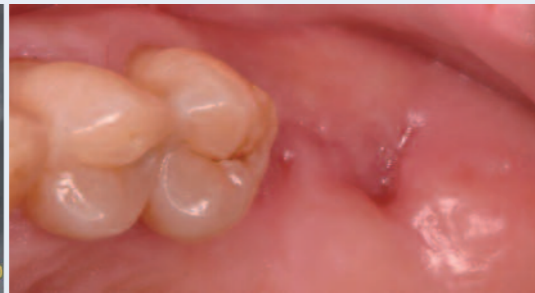

Fig. 2
Six weeks after extraction of the left maxillary molars, epithelialization of the sites was evident.

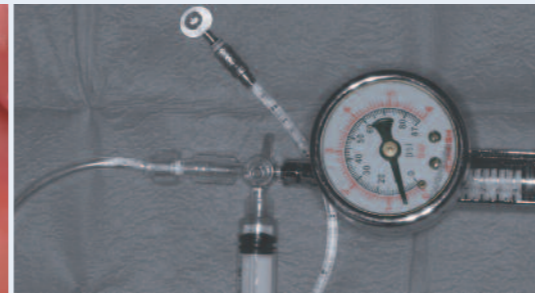


Fig. 3
A barometric pump was attached presurgically to the balloon-harboring device.

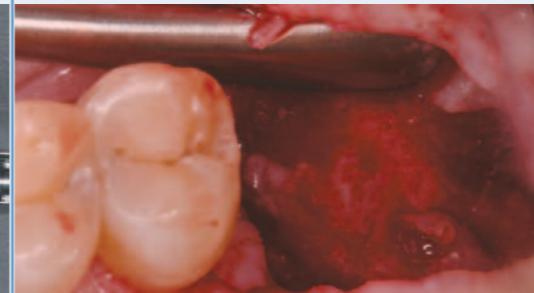


Fig. 4
A full-thickness mucoperiosteal flap was raised, revealing the alveolar crest.

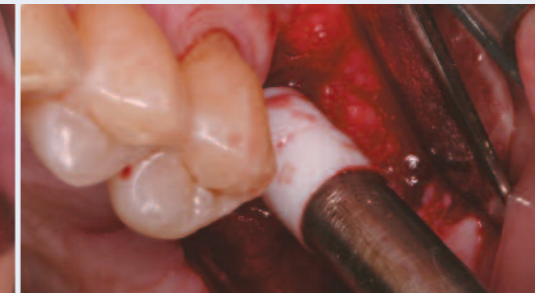

Fig. 5
The Teflon stopper prevented the Schneiderian membrane from being torn, as the floor of the maxillary sinus was in-fractured.

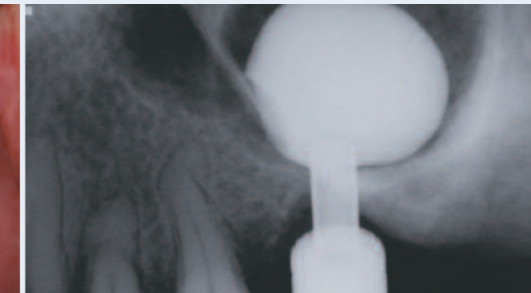

Fig. 6
Periapical radiograph of balloon-harboring device after being filled with the contrast material.

should be considered a predictable and effective therapeutic modality.⁹ A systematic review by Wallace and Froum in 2003 found that implant survival in sinuses grafted with the lateral window technique averaged 91.8% (range: 61.7-100%).¹⁰

On the other hand, potential complications include tearing of the membrane, bleeding, infection, and sinus obstruction.¹¹ The technique requires considerable surgical skill and time, is costly, and commonly causes patient edema and discomfort.

A less invasive alternative was introduced by Summers¹² in 1994. Known as the osteotome or bone-added osteotome sinus-floor elevation (BAOSFE) technique, this approach uses a number of tapered osteotomes to push bone apically beneath the tented membrane while enlarging and deepening the osteotomies. However, it has been shown to yield an average bone height of only 3 ± 0.8 mm.¹³ Membrane perforation and tears are also complications,¹⁴ although expert technique and dedicated instrumentation can minimize that risk.¹⁵

To enable minimally invasive augmentation of more severely atrophic posterior maxillary sites, a modification of the BAOSFE technique was introduced in 2006.¹⁶ The minimally invasive antral membrane balloon elevation (MIAMBE) procedure uses a dedicated balloon and other instrumentation to elevate the membrane through a 3mm to 3.5mm diameter osteotomy. The procedure can be learned quickly, typically can be executed in less than an hour, and may reduce the complications, discomfort, disfigurement, and disability associated with the lateral side window augmentation approach.

The following clinical presentation illustrates the use of the MIAMBE technique.

Clinical Case Presentation

The patient was a 47-year-old female who presented complaining of mobility of her left maxillary molars. Advanced periodontal disease was diagnosed, and a CT scan and panoramic radiographs were taken to ascertain the maxillary bone dimensions, mucosal thickness, sinus anatomy, and location of the major blood vessels. The CT scan (Fig. 1) revealed the alveolar bone directly below the sinus to be approximately 10mm wide but only 2mm high.

A treatment plan was developed, calling for extraction of the maxillary left first and second molars. After healing of the extraction sites, the MIAMBE technique would be used to augment the ridge, followed by simultaneous placement of two dental implants.

The teeth were extracted, and after six weeks, the patient returned for the sinus-elevation procedure and implant placement (Fig. 2). Approximately 40ml of the patient's blood was drawn by venous puncture and processed to obtain platelet-rich fibrin (PRF). The dedicated barometric pump was connected to the balloon-harboring device (MIAMBE, Netanya, Israel). This is a stainless steel tube that connects on its proximal end to the dedicated inflation syringe and on its distal end has a screw-in mechanism that secures the device into the osteotomy site (Fig. 3). Immediately pre-operatively, the balloon was inflated extraorally and inspected to confirm its integrity.

Local anesthesia was administered to the patient, and a full-thickness mucoperiosteal flap was raised to expose the alveolar crest (Fig. 4). In the first molar position, a 1mm-deep osteotomy was created using a piezosurgical diamond tip. A dedicated osteotome connected to a Teflon stopper was then inserted into the osteotomy and gently tapped with a hammer; infracturing the sinus floor (Fig. 5). The purpose of the stopper is to limit the extent of the osteotome's penetration into the sinus, with the aim of ensuring the integrity of the Schneiderian membrane. After the integrity of the sinus membrane was confirmed by Valsalva maneuver and direct visualization, the metal sleeve of the balloon-harboring device was inserted into the osteotomy to a point 1mm beyond the sinus floor.

A coronary angioplasty inflation syringe (Merit Medical, Galway, Ireland) filled with diluted contrast material was screwed into the balloon-harboring device. The syringe was then slowly depressed, inflating the balloon to two standard atmospheres. Typically, the pressure drops to 0.5 atmospheres once the balloon emerges from the metal sleeve. Inflation of the balloon with approximately 1cc of contrast fluid then continued. A periapical radiograph was taken to verify the balloon's positioning. Fig. 6 demonstrates how well the filled balloon conforms to the contours of the sinus cavity along the septum.

Once the desired elevation was obtained, the balloon was left inflated for five minutes to reduce the membrane's elasticity. The balloon was then deflated by retracting the fluid back into the syringe, and the balloon-harboring device was removed from the osteotomy.

Using a bone syringe, Endobon® Xenograft Granules* (BIOMET 3i), mixed with the PRF prepared pre-surgically, were inserted into the newly created space beneath the membrane (Fig. 7). A radiograph taken at this point (Fig. 8) confirmed that the sinus floor had been elevated by approximately 11mm. Additional xenograft was added (Fig. 9), and when the elevated sinus was completely filled with the xenograft, a second osteotomy was created in the second molar site. Two 13mm length x 5/4mm diameter NanoTite™ Tapered PREVAIL® Implants (BIOMET 3i) were then inserted in the osteotomies (Fig. 10). The design of these implants incorporates platform switching to aid in crestal bone height preservation. Two EP® Healing Abutments were placed into the implants, and the soft-tissue flaps were secured with resorbable sutures. The tissues were approximated, and the patient was instructed to limit herself to a soft diet for 10 days.

After five months, excellent soft-tissue healing was noted around the healing abutments (Fig. 11). Radiographic examination also confirmed that the crestal bone height gained after the sinus elevation had been maintained around the platform-switched implants.

The EP Healing Abutments were removed, and the soft-tissue response around the implants was found to be excellent (Fig. 12). Certain® Implant Impression Copings were attached to the implants, and an impression was made. Corresponding Certain (4mm restorative seating surface) Laboratory Analogs were mated to the impression copings in the impression (Fig. 13), and a soft-tissue model was made prior to pouring of the impression in stone.

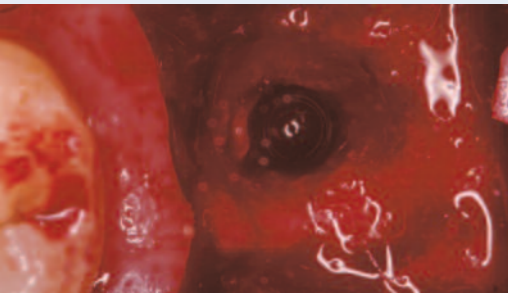


Fig. 7
Occlusal view of the osteotomy in the first molar site, showing Endobon® Xenograph Granules mixed with PRF inserted into the space created by the newly elevated sinus floor.

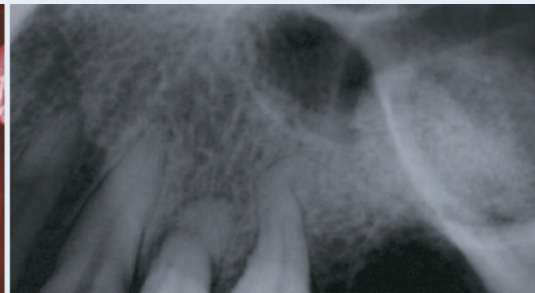

Fig. 8
Periapical radiograph taken immediately after filling the sinus with xenograft bone-replacement material.

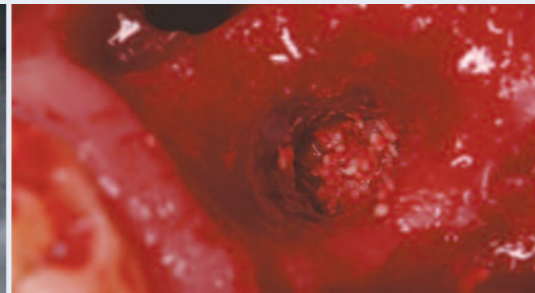


Fig. 9
After the first graft site was completely filled with the xenograft material, a second osteotomy was created in the second molar position.

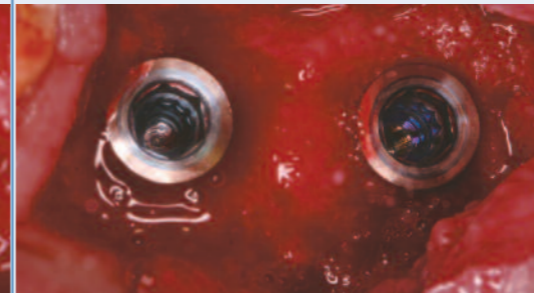

Fig. 10
Two NanoTite™ Tapered PREVAIL® Implants in place. Note that the occlusal surfaces of the implants are clearly visible at the time of implant placement.

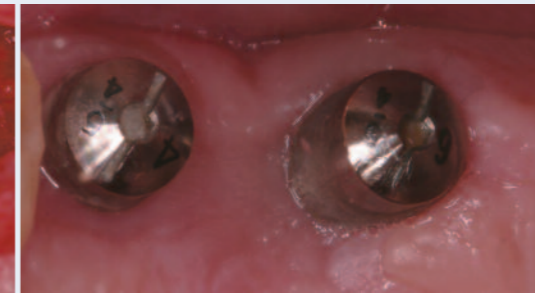


Fig. 11
Occlusal view of healthy soft-tissue healing surrounding two EP® Healing Abutments, which were placed at the time of implant placement.

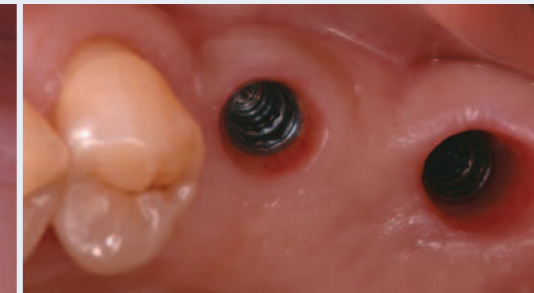

Fig. 12
Occlusal view taken five months after implant placement. Note the excellent soft tissue response around the platform-switched implants.



Fig. 13
Photograph of the intaglio surface of the impression. The corresponding Certain® Laboratory Analogs have been mated to the impression copings in the impression.

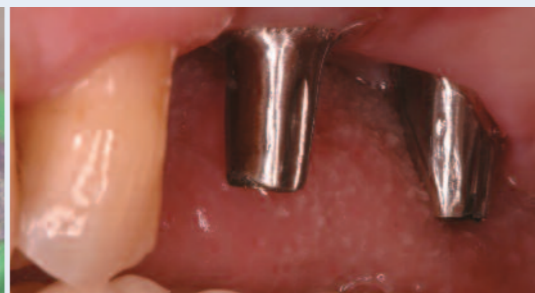

Fig. 14
The prepared GingiHue® Posts were placed into the internal interfaces of the implants.

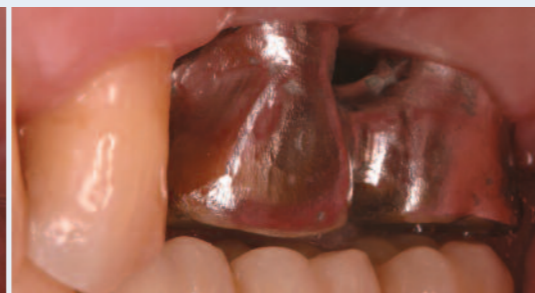

Fig. 15
The splinted metal copings were tried in over the abutments to confirm accuracy of fit and returned to the lab for porcelain application.

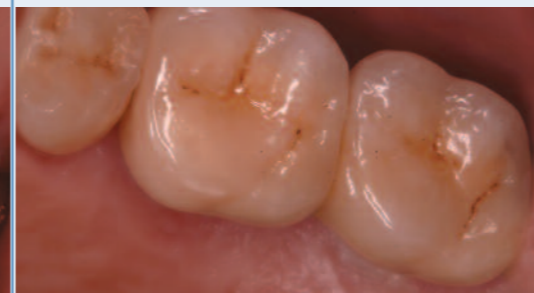

Fig. 16
The PFM restoration was seated, and occlusal equilibration was done.

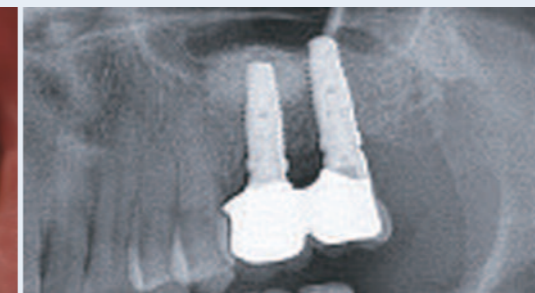

Fig. 17
The 12-month post-restorative panoramic radiograph.

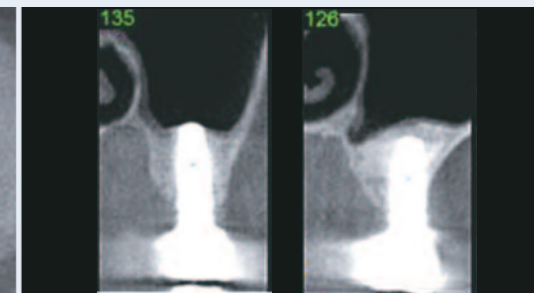


Fig. 18
CT axial slices of the two implants taken 12 months after definitive restoration.

In the laboratory, two GingiHue Posts were placed onto the master cast and modified. Splinted metal copings were fabricated for the modified abutments, and these were sent to the dental office for try-in. The patient returned, and the prepared GingiHue Posts were placed into the internal interfaces of the implants (Fig. 14). The splinted metal copings were tried in over the abutments to confirm accuracy of fit (Fig. 15) and returned to the lab for porcelain application.

Figure 16 shows the porcelain-fused-to-metal restoration in place after occlusal equilibration. A panoramic radiograph and CT scan (Figs. 17 and 18) confirmed the success of the sinus graft and osseointegration of the implants achieved using the MIAMBE technique.

Discussion

Kfir et al in two separate studies^{17,18} reported six-nine-month survival rates of 95% and 97% respectively for implants immediately placed in 145 patients who underwent the MIAMBE procedure. In both investigations, the procedure was completed in less than an hour, on average, and incremental bone height consistently exceeded 8-10mm. A 95.2% implant success rate was reported in a separate 2009 study¹⁹ of 26 patients receiving the procedure who had antral septa of the maxillary sinus. This is considered a relative contraindication for the closed osteotome procedure.

Macroscopic and microscopic evaluation of four methods of indirect sinus-floor elevation investigated *ex vivo* using 36

bisected pigs' heads found that when elevation was conducted using an inflatable balloon, no perforation of the Schneiderian membrane occurred, in contrast with more traditional techniques.²⁰ If the membrane ruptures during the MIAMBE procedure, the procedure must be aborted.

It is important to note that although immediate implant placement was carried out in the case reported here, a minimum amount of residual subantral bone must be present to enable primary implant stabilization and subsequent osseointegration. In the experience of the author, a minimum ridge height of 2-3mm must be present. In the presence of even that minimal amount, the design of the PREVAIL® Tapered Implant enables adequate fixation of the implant neck in the bone.

Clinical Relevance

When atrophy of the subantral alveolar ridge complicates placement of dental implants, the minimally invasive antral membrane balloon elevation technique described in this report can enable substantial elevation of the sinus floor. If a minimum of 2-3mm of residual subantral bone height is present, it may be possible simultaneously to place and achieve primary stability of properly designed tapered implants. This technique is simpler and less expensive than more invasive techniques and may avoid the complications associated with lateral window-elevation techniques. The design of the PREVAIL Implant not only allows for high primary stability, it also allows this technique to be employed in minimal amounts of pre-existing bone under the sinus.

References

1. Garg AK. Augmentation grafting of the maxillary sinus for placement of dental implants: Anatomy, physiology, and procedures. *Implant Dent* 1999;8:36-46.
2. Truhlar RS, Orenstein IH, Morris HF et al. Distribution of bone quality in patients receiving endosseous dental implants. *J Oral Maxillofac Surg* 1997;55(12 Suppl 5):38-45.
3. Toffler M. Treating the atrophic posterior maxilla by combining short implants with minimally invasive osteotome procedures. *Pract Proced Aesthet Dent* 2006;18:301-308.
4. Langer B, Langer L, Harman I et al. The wide fixture: a solution for special bone situations and a rescue for the compromised implant. *Int J Oral Maxillofac Implants* 1993;8:400-408.
5. Balshi TJ, Wolfinger GJ. Management of the posterior maxilla in the compromised patient: historical, current, and future perspectives. *Periodontology* 2000 2003;33:67-81.
6. Verhoeven JW, Cune MS, Terlouw M et al. The combined use of endosteal implants and iliac crest onlay grafts in the severely atrophic mandible: a longitudinal study. *Int J Oral Maxillofac Surg* 1997;26:351-357.
7. Hochwald DA, Davis WH. Bone grafting in the maxillary sinus floor. In Worthington P, Brånemark P-I (eds.) *Advanced Osseointegration Surgery: Applications in the Maxillofacial Region*. Chicago: Quintessence, 1992:175-181.
8. Tatum H. Maxillary and sinus implant reconstructions. *Dent Clin North Am* 1986;30:207-229.
9. Jensen OT, Shulman LB, Block M et al. Report of the Sinus Consensus Conference of 1996. *Int J Oral Maxillofac Implants* 1998;13 Suppl: 11-45.
10. Wallace SS, Froum SJ. Effect of maxillary sinus augmentation on the survival of endosseous dental implants. A systematic review. *Ann Periodontol* 2003;8:328-343.
11. Mazor Z, Kfir E. Minimally invasive antral membrane balloon elevation to treat previous sinus augmentation failure: A case report. *J Implant Adv Clin Dent* 2009;1:49-57.
12. Summers RB. The osteotomes technique: part 3 – less invasive methods of elevating the sinus floor. *Compend Contin Educ Dent* 1994;15:698-710.
13. Nkenke E, Schlegel A, Schultze-Mosgau S et al. The endoscopically controlled osteotome sinus floor elevation: A preliminary prospective study. *Int J Oral Maxillofac Implants* 2002;17:557-566.
14. Berengo M, Sivoletta S, Majzoub Z et al. Endoscopic evaluation of the bone-added osteotome sinus floor elevation procedure. *Int J Oral Maxillofac Surg* 2004;33:189-194.
15. Toffler M. Staged sinus augmentation using a crestal core elevation procedure and modified osteotomes to minimize membrane perforation. *Pract Proced Aesthet Dent* 2002;14:767-774.

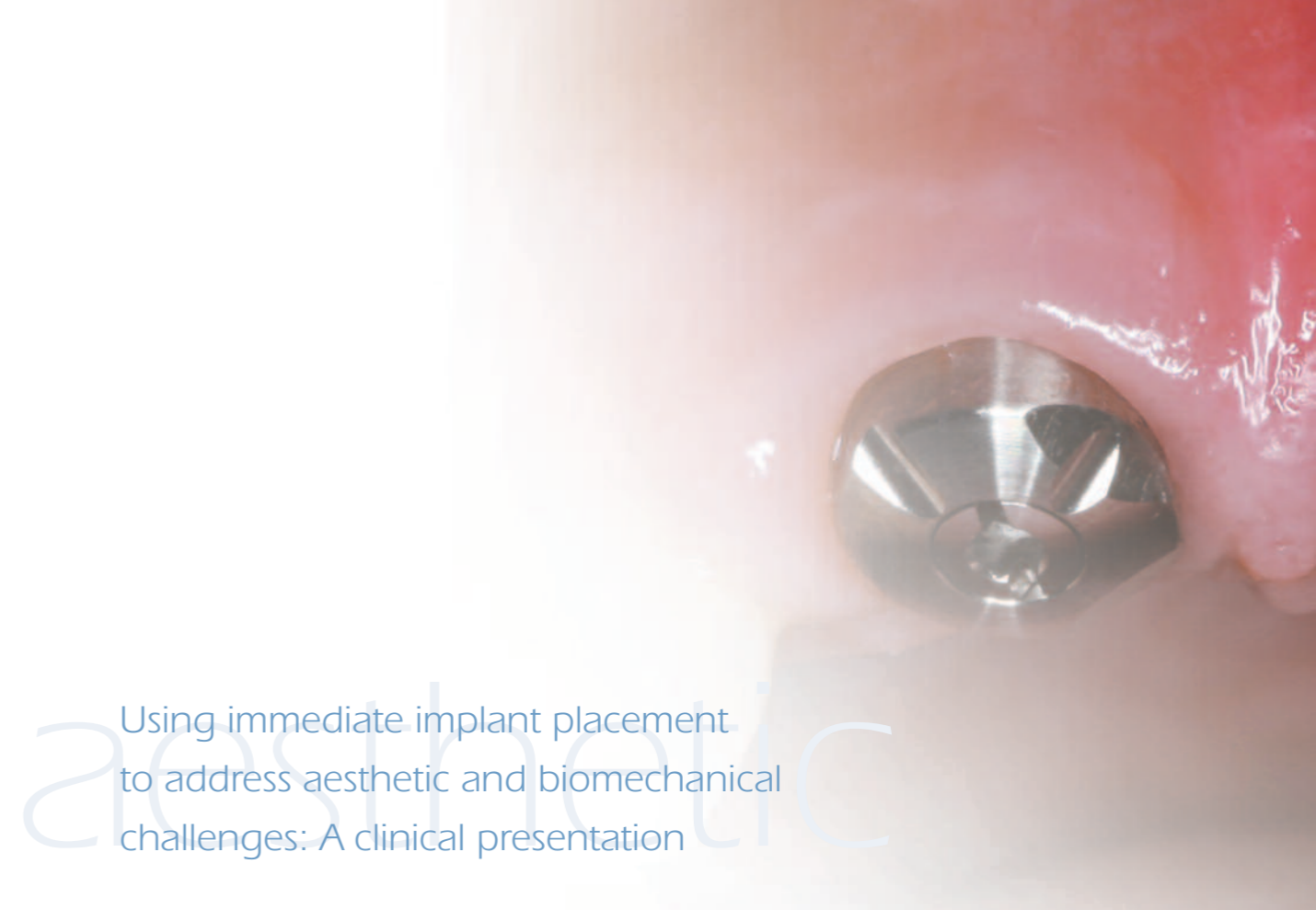
16. Kfir E, Kfir V, Mijiritsky E et al. Minimally invasive antral membrane balloon elevation followed by maxillary bone augmentation and implant fixation. *J Oral Implantol* 2006;32:26-33.
17. Kfir E, Kfir V, Eliav E et al. Minimally invasive antral membrane balloon elevation: report of 36 procedures. *J Periodontol* 2007;78:2032-2035.
18. Kfir E, Goldstein M, Yerushalmi I et al. Minimally invasive antral membrane balloon elevation – results of a multicenter registry. *Clin Implant Dent Relat Res* 2009;11:e83-e91.
19. Kfir E, Goldstein M, Rafaelov R et al. Minimally invasive antral membrane balloon elevation in the presence of antral septa: A report of 26 procedures. *J Oral Implantol* 2009;35:257-267.
20. Stelzle F, Benner K-U. Evaluation of different methods of indirect sinus-floor elevation for elevation heights of 10mm: An experimental ex vivo study. *Clin Implant Dent Relat Res*. Published online 3 Aug 2009.

*Sinus lift indication for Europe only.

Ziv Mazor, DMD



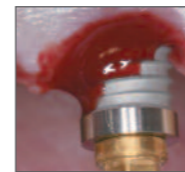Dr. Ziv Mazor graduated from the periodontal department of Hadassah School for Dental Medicine in Jerusalem, Israel where he served as clinical instructor and lecturer for undergraduate and postgraduate dental students. He maintains a private practice limited to periodontal and implant dentistry in Raanana, Israel and is engaged in clinical research in the field of bone augmentation and sinus floor elevation. Dr. Mazor is a well-published author on these subjects and has lectured extensively both nationally and internationally. He is the past president of the Israeli Periodontal Society.



aesthetic

Using immediate implant placement to address aesthetic and biomechanical challenges: A clinical presentation

Pär-Olov Östman, DDS, PhD



Immediate implant loading has become an attractive option for meeting some of the aesthetic and biomechanical challenges associated with replacing single teeth with implants, particularly in the aesthetic zone. This article reviews some of the literature relating to immediately loading single-implant sites. A case is presented in which implants were placed and immediately non-occlusally loaded to treat a young man who had suffered a traumatic injury to his maxillary central incisors.

Key Words: immediate occlusal loading, immediate non-occlusal loading, single-tooth restoration, Encode® Impression System

Introduction

The loss of a single tooth has been documented to be the most common indication for implant treatment.¹ In the aesthetic zone, implant-supported single-tooth replacement is one of the most challenging situations confronting the clinician, especially when a two-stage protocol is being employed. In the wake of tooth loss, both hard- and soft-tissue resorption is the inevitable consequence. The volumes of both the hard and soft tissues must be evaluated carefully, and in cases of severe resorption, augmentation may be required. With every exposure of the alveolar bone, the biologic width also must be reestablished. In contrast, placing and immediately loading an implant with a provisional restoration may forestall some of these negative consequences and increase the potential for achieving an optimal emergence profile.

From the patient's perspective, the loss of a single tooth often is traumatic, and phonetics may be compromised during the traditional two-stage placement healing period. The ability to reduce the number of surgeries and total treatment time also appeals to many people.

For all of these reasons, accelerated implant-loading procedures have become an attractive treatment option. As this has occurred, clinicians have used a variety of terms to refer to the different possible approaches. For the purposes of this article, immediate occlusal loading (IOL) refers to the placement (within 24 hours of implant placement) of a provisional restoration that is in contact with the opposing dentition in centric occlusion. Immediate non-occlusal loading (INOL) refers to instances in which the immediate restoration is not in

Pär-Olov Östman, DDS, PhD (continued)

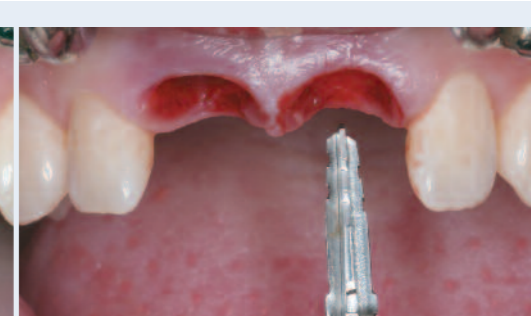
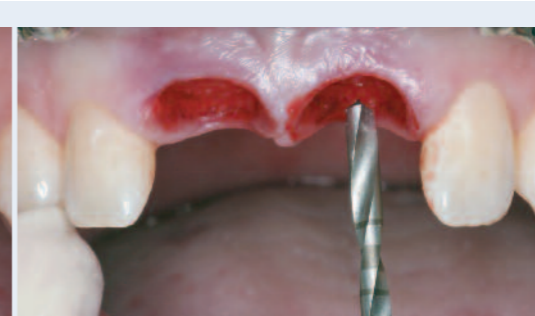
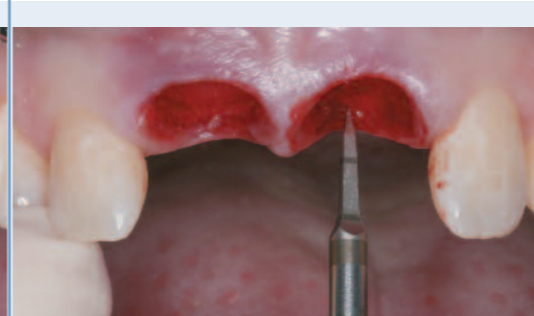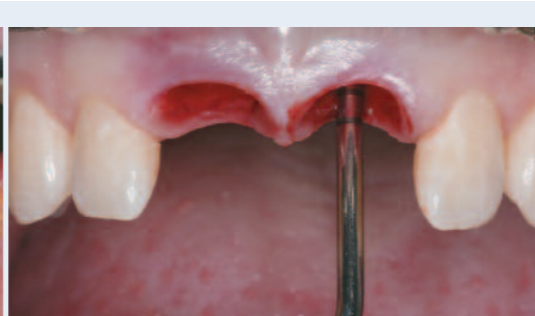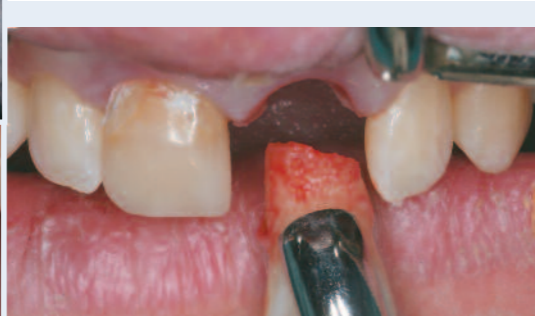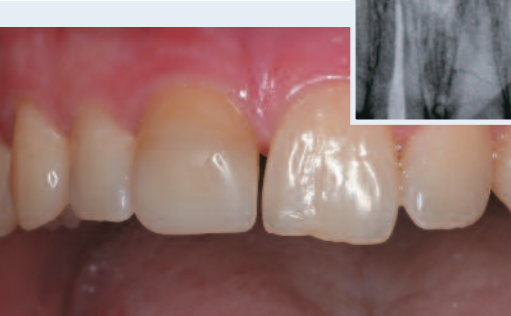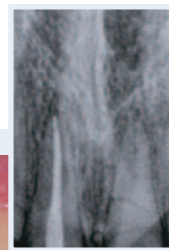Fig. 1
Pre-operative clinical photograph of hopeless maxillary central incisor teeth. Periapical radiograph (inset) demonstrates sufficient bone volume for dental implants.

Fig. 2
Teeth Nos. 8 & 9 [11 and 21] were carefully extracted. The right central incisor demonstrated root resorption, and the left central incisor was fractured.

Fig. 3
The sockets were debrided with hand instruments. An implant depth gauge was used to ensure the buccal plates were intact.

Fig. 4
An ACT® Pointed Starter Drill was used to properly orient the osteotomies within the extraction sockets.

Fig. 5
A 2mm diameter twist drill was advanced to the desired depth for preparation of the osteotomy. The bone quality was determined to be Type IV (soft).

Fig. 6
Following the manufacturer's guidelines for placement of Tapered Implants, 3.25mm and 4.0mm diameter x 15mm length Quad Shaping Drills were advanced into the osteotomies to full depth.

contact with the opposing dentition in centric occlusion. When a provisional restoration is placed more than 24 hours after implant placement but less than three months post-surgically, such restorations may be referred to as early (as opposed to immediate) loading.

Scientific evidence of the predictability of both early² and immediate loading procedures has steadily accumulated. Ericsson and colleagues³ performed a prospective clinical and radiographic study comparing immediately loaded single-tooth implants to single-tooth implants restored according to a traditional two-stage protocol. The immediate-loading group consisted of 14 patients, and the two-stage control group included eight patients. All patients had single-tooth losses anterior to the molars, were non-smokers, and had sufficient bone to accommodate a 3.75mm diameter implant of at least 13mm in length. Two of the 14 implants in the immediately loaded group were lost after five months in function. The remaining 12 implants were stable. No implant losses were recorded in the two-stage control group. Analysis of radiographs from both groups showed a mean change of bone support of about 0.1mm at the 12-month follow-up.

In another prospective clinical study conducted by Hui and co-workers,⁴ 24 patients were followed. Single-tooth implant placement was done according to an immediate provisional protocol in 24 patients, including 13 who had immediate implant placement after tooth extraction. All implants were placed in the aesthetic zone using a surgical protocol aimed at enhancing primary implant stability and

achieving a minimal insertion torque of at least 40Ncm. Within the follow-up period of between one and 15 months, all implants in the 24 patients were stable. No crestal bone loss of greater than one thread was detected. The aesthetic results were considered satisfactory by all patients.

Calandriello et al⁵ reported on a prospective multicenter study including 44 patients treated with 50 wide-platform implants and provided with provisional crowns in centric occlusion at the time of surgery. During follow-up periods ranging from six months to one year, no implants were lost. Marginal bone levels were found in accordance with normal biologic width requirements. Resonance frequency analysis (RFA) showed high and consistent implant stability.

Rocci and co-workers⁶ evaluated 97 implants, including 27 placed at single-tooth sites in flapless surgeries and immediately loaded. Nine implants placed in eight patients failed during the first eight weeks of loading. Five of the eight patients with failed implants lost single-tooth implants, including two that had been inserted in fresh extraction sites. Three patients lost four implants in partial restorations. The marginal bone resorption was 1.0mm on average during the first year of loading, 0.4mm during the second year, and 0.1mm during the third year.

Lorenzoni et al⁷ evaluated clinical outcomes of immediately loaded implants 12 months after placement in the maxillary incisal region. The implants were inserted with torque values of up to 45Ncm and immediately restored with unsplinted

acrylic resin provisional crowns. Patients were provided with occlusal splints. No implant failed up to 12 months after insertion. Mean coronal bone-level changes at six and 12 months were 0.45 and 0.75mm. Bone resorption after six and 12 months was less than that evaluated for implants placed in a standard two-stage procedure.

Degidi and co-workers⁸ evaluated 111 single implants that were immediately non-functionally loaded. All implants were placed with a minimum insertion torque of 25Ncm. After five years of follow-up, the overall survival rate was 95.5%. The authors found a significant difference between healed and immediate post-extraction sites (100% and 92.5%, respectively) and type of bone (100% for Type I, versus 95.5% for Type IV).

In a prospective, single-center study,⁹ the present author and co-workers enrolled 35 patients requiring implant treatment. Surgical implant-placement requirements consisted of a final torque of at least 25Ncm prior to final seating and an implant-stability quotient above 55. A total of 102 implants (66 maxillary and 36 mandibular) were placed, mostly in posterior regions (65%) and soft bone (69%). A total of 44 prosthetic constructions were evaluated, consisting of 14 single-tooth restorations (7 maxillary and 7 mandibular), 26 fixed partial dentures, and four complete fixed restorations. All provisional constructions were delivered within one hour, and the final constructions were placed after four months. Implants were monitored for clinical and radiographic outcomes at 3-, 6-, and 12-month follow-up examinations. Only one implant failed, and it was

Author	Type of Study	No. Patients	No. Implants Loaded	Follow-Up Years	Lost Implants	Survival Rate %
Ericsson et al ³	Prosp	14	14	1	2	86%
Hui ⁴	Prosp	24	24	1-15 months	0	100%
Calandriello et al ⁵	Prosp	44	50	6-12 months	0	100%
Rocci et al ⁶	Retro	27	27	3	5	81.5%
Lorenzoni et al ⁷	Retro	12	12	1	0	100%
Degidi et al ⁸	Retro	111	111	5	5	95.5%
Östman et al ⁹	Prosp	14	14	1	0	100%
Total		246	252	-	-	

Table 1. Published articles on immediate loading of single-tooth maxillary and mandibular restorations.

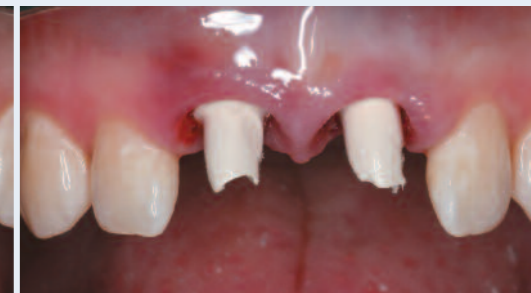
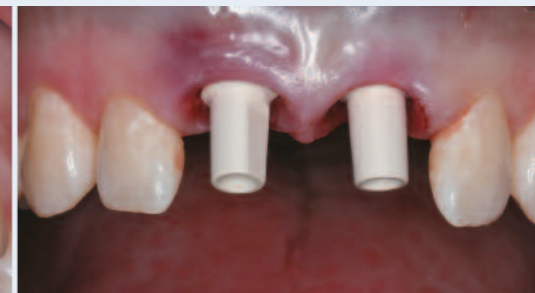
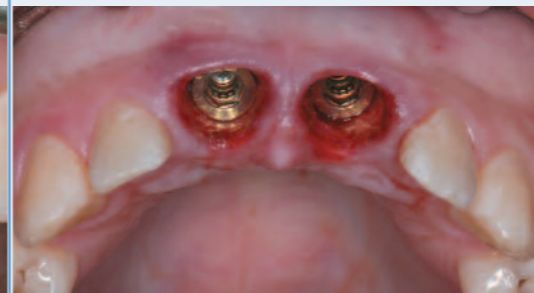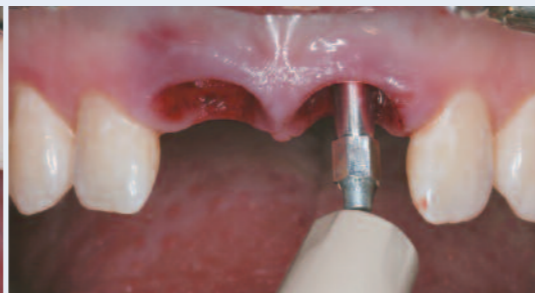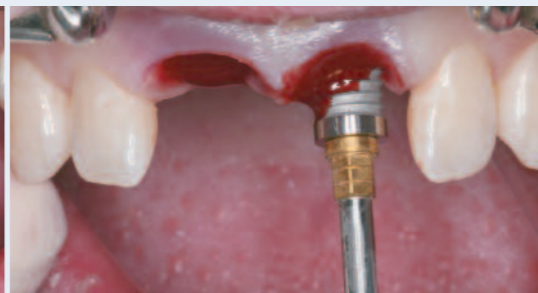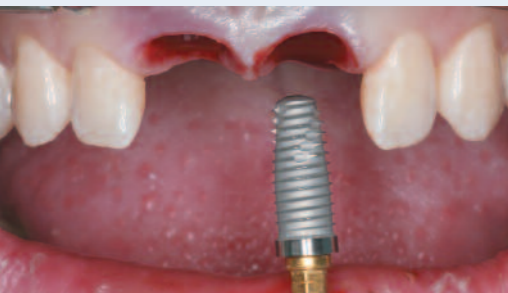Fig. 7
Two 5mm diameter x 15mm length NanoTite™ Tapered PREVAIL® Implants were placed with the handpiece, then hand tightened with a High Torque Driver. The final torque measured 70Ncm.

Fig. 8
No irrigation was used during implant placement. The patient's own blood was allowed to wick onto the surface of the implants.

Fig. 9
An Osstell SmartPeg was placed into the internal interface of each implant, and ISQ readings greater than 70 were recorded.

Fig. 10
Occlusal view of the restorative seating surfaces of the implants and the depth of the soft tissue present around the implants.

Fig. 11
PreFormance® Posts were selected for fabrication of the provisional restorations. The posts were secured with abutment screws tightened to 20Ncm.

Fig. 12
The PreFormance Posts were trimmed and modified for occlusal clearance.

not one of those supporting a single-tooth restoration. Table I summarizes these findings regarding immediately loaded single-tooth restorations.

Although the above-referenced papers include a limited number of samples, experimental studies and histological analysis of clinically retrieved implants have shown similar and sometimes better bone-implant contact (BIC) for immediately loaded implants, compared to delayed cases. Piattelli et al¹⁰ compared histologically non-submerged unloaded implants with early-loaded titanium-screw implants in monkeys. They found a tight contact of new bone to the implant surfaces in all samples examined. Moreover, around the necks of the early-loaded screws, a pattern of lamellar cortical bone was noted, thicker than in the unloaded implants. In a pilot study,¹¹ the bone reactions to early loaded titanium plasma-sprayed implants were analyzed in a monkey model. Twenty implants were immediately loaded, and four implants functioned as controls. The result showed a BIC of 67.2% of the maxillary implant surfaces (10 implants) and 80.7% BIC of mandibular implant surfaces (10 implants). No differences were found in the percentage of bone-implant contact in the control implants. However, the loaded implants had a more compact appearance compared to the controls.

Testori et al¹² found a higher BIC for immediately loaded OSSEOTITE® (BIOMET 3i) Implants (64.2%), compared to submerged implants (38.9%). Rocci et al¹³ retrieved nine oxidized titanium implants after five to nine months in

function. Two implants had been loaded the same day, whereas seven implants were loaded after two months of healing. Morphometric measurements of the two immediately loaded implants showed a mean BIC value of 92.9%. The corresponding value for the six early loaded implants was 81.4%. Frost¹⁴ has postulated that both overly modest and excessive loading can result in negative tissue reactions.

Clinical Presentation

The following clinical presentation illustrates the immediate placement and provisionalization of implants in the anterior maxilla, using an INOL protocol.

The patient was a 22-year-old male who presented with hopeless maxillary central incisors due to trauma. Clinical and radiographic examination revealed root resorption of tooth No. 8 [11] and a root fracture of tooth No. 9 [21] (Fig. 1 and inset of PA). Sufficient bone volume was present for a fixed implant-supported prosthesis. Since the patient desired a fixed solution for these two teeth, the treatment plan included extractions and simultaneous implant placement with immediate provisionalization.

Following administration of local anesthesia by infiltration, teeth Nos. 8 and 9 [11 and 21] were extracted (Fig. 2), and the sockets were carefully debrided. Examination of the socket walls revealed intact facial bone in both sites (Fig. 3). Preparation of the osteotomies began with an ACT® Pointed Starter Drill (Fig. 4). A 2mm diameter twist drill was then advanced into the osteotomies (Fig. 5). The bone

quality was determined to be Type IV (soft bone). Next, 3.25mm and 4.0mm diameter x 15mm length Quad Shaping Drills (QSD) were used to full depth (Fig. 6). Following the manufacturer's guidelines for placement of NanoTite™ Tapered Implants in soft bone, the 4.0mm diameter QSD was the last drill used, thus undersizing the osteotomies by one drill diameter. A Depth/Direction Indicator (NTDI) was placed into the prepared osteotomies to confirm the accuracy of the preparations and to visualize where the implant-abutment junction should be positioned. Two 5mm diameter x 15mm length implants were placed (Fig. 7) with the handpiece. No irrigation was used; rather the patient's own blood was allowed to wick onto the surface of the implants (Fig. 8). The insertion torque of the implants reached the limit preset on the drilling unit (50Ncm). An Osstell SmartPeg (Osstell Mentor Device, Integration Diagnostics, Gothenberg, Sweden) was placed into the internal interface of each implant (Fig. 9), and ISQ readings greater than 70 were recorded.

Figure 10 shows the seating surfaces of the implants and the depth of the soft tissue present around the implants. Two PreFormance Posts of 5mm diameter x 4mm trans-tissue height were selected to gain as much soft-tissue support as possible. The posts were placed into the implants and secured with abutment screws tightened to 20Ncm (Fig. 11). The PreFormance Posts were prepared and modified for occlusal clearance (Fig. 12). An alginate impression was made prior to tooth extraction for fabrication of the provisional prosthesis. Splinted provisional

crowns were made with ProTemp™ 4 Garant (3M ESPE, St. Paul, Minnesota, USA) (Fig. 13). The material was allowed to set per the manufacturer's instructions. The restoration was then removed, trimmed, and polished. It was tried in intraorally over the posts and then cemented with ProTemp 3 Garant (3M ESPE) (Fig. 14). The occlusion was adjusted following the protocol for non-occlusal loading. A periapical radiograph was taken (inset), and the patient was released with instructions to avoid hard foods and use proper oral hygiene.

Healing was uneventful. At the four-month evaluation, healthy soft tissue was noted around the provisional restorations. The crowns and PreFormance Posts were removed, and Encode® Healing Abutments were placed (Fig. 15). An impression was made with a closed stock tray filled with heavy body polyvinylsiloxane impression material (AFFINIS microSystem™, Coltène Whaledent, Switzerland). The impression material was allowed to set, then removed. The impression was inspected for accuracy and to ensure that the codes on the occlusal surfaces of the abutments were accurately captured in the impression. The posts and provisional restorations were replaced, and the patient released.

In the laboratory, the impression was poured in die stone for fabrication of a master cast. The cast and Encode Work Order were then sent to a BIOMET 3i PSP Facility for fabrication of Encode Zirconia Abutments. The abutments were returned to the commercial laboratory for fabrication of two Denzir® zirconia crowns (Fig. 16).

Pär-Olov Östman, DDS, PhD (continued)

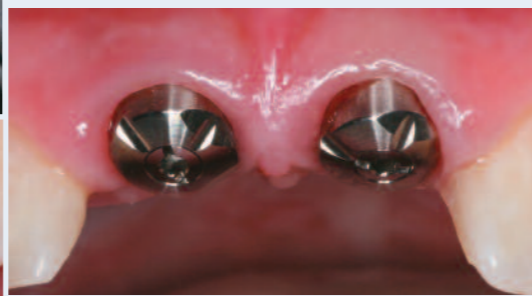
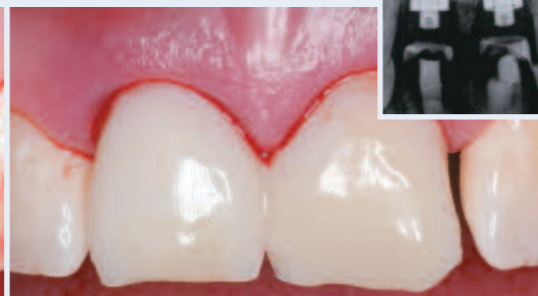
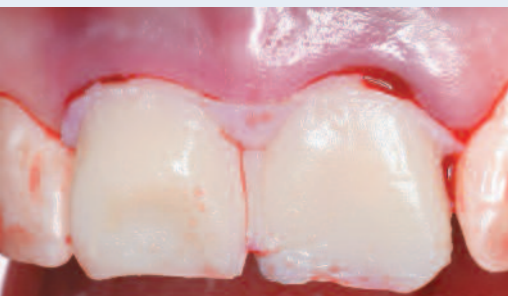Fig. 13
A splinted provisional restoration was fabricated chairside. Once the material set, the restoration was removed, trimmed, and polished.

Fig. 14
The splinted restoration was tried in intraorally over the posts and then cemented with provisional cement. A periapical radiograph was taken (inset).

Fig. 15
Four months later, the provisional restoration and the PreFormance® Posts were removed, and Encode® Healing Abutments were placed. An impression was made with a closed stock tray.

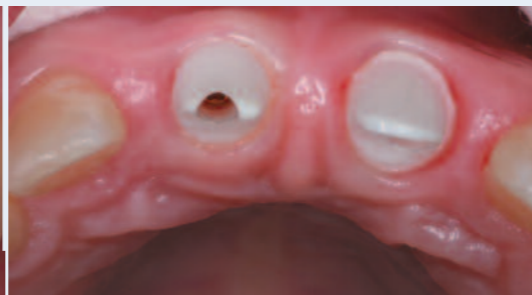
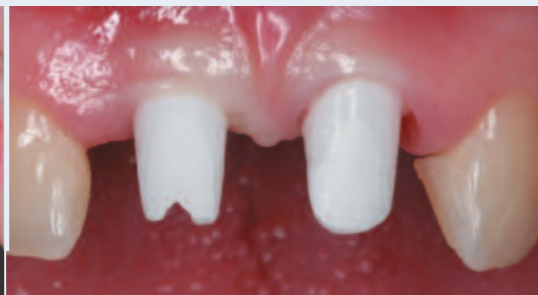
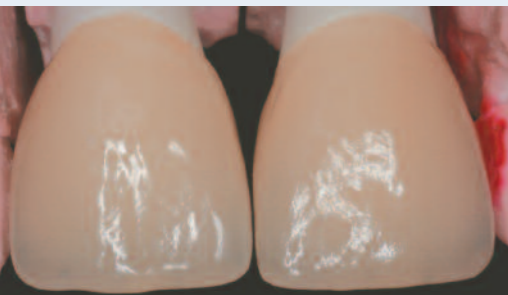Fig. 16
In the laboratory, two zirconia crowns were fabricated for the Encode Zirconia Abutments.

Fig. 17
The definitive Encode Zirconia Abutments were placed and secured with Gold-Tite® Abutment Screws tightened to 20Ncm.

Fig. 18
Occlusal view of the Encode Zirconia Abutments in place. The screw-access openings were blocked out, before cementation of the restorations.

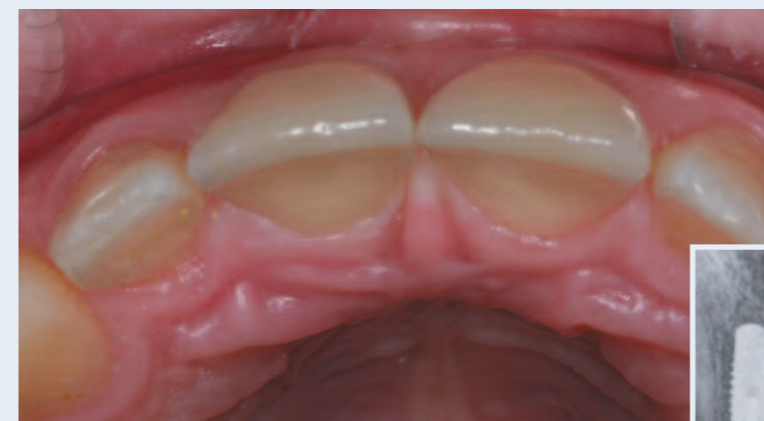

Fig. 19
Occlusal view of the definitive restorations in place. A periapical radiograph was taken to ensure that excess cement was removed from the subgingival margins (inset).

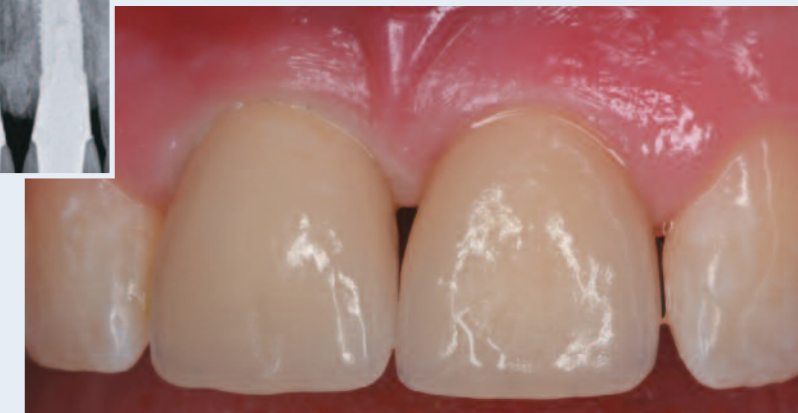

Fig. 20
Facial view of the definitive zirconia restorations supported by Encode Zirconia Abutments.

The patient returned to the dental clinic. The provisional restoration and abutments were removed, and the definitive Encode® Zirconia Abutments were placed. Gold-Tite® Abutment Screws were placed into the abutments and tightened to 20Ncm (Figs. 17 and 18). The screw-access openings were blocked out, and the crowns were cemented with RelyX™ Luting Cement (ESPE, 3M, St. Paul, Minnesota, USA) (Figs. 19 and 20). A periapical radiograph was taken to ensure that all the excess cement was removed from the subgingival margins (Inset), and the patient was released with oral hygiene instructions.

Clinical Relevance

A number of studies have evaluated immediately loaded single-tooth sites located throughout the mouth. When primary stability has been achieved, good to excellent short- to medium-term results have been reported. Furthermore, immediate loading protocols allow treatment to be accomplished in less time, provide patients with immediate functional, aesthetic, and psychological benefits, and help to

better maintain the soft- and hard-tissue architecture in the wake of implant placement. Additional long-term data evaluating the benefits and risks of immediate loading are needed, as well as guidelines for choosing occlusal loading versus non-occlusal loading.

References

1. Cornolini R, Cangini F, Covani U et al. Immediate loading of implants with 3-unit fixed partial dentures: a 12-month clinical study. *Int J Oral Maxillofac Implants* 2006; 21(6):914-918.
2. Andersen E, Haanaes HR, Knutsen BM. Immediate loading of single-tooth ITI implants in the anterior maxilla: a prospective 5-year pilot study. *Clin Oral Implants Res* 2002; 13(3):281-287.
3. Ericsson I, Nilson H, Lindh T et al. Immediate functional loading of Branemark single tooth implants: An 18 month clinical pilot follow-up study. *Clin Oral Implants Res* 2000; 11(1):26-33.
4. Hui E, Chow J, Li D et al. Immediate provisional for single-tooth implant replacement with the Branemark system: Preliminary report. *Clin Implant Dent Relat Res* 2001; 3(2):79-86.
5. Calandriello R, Tomatis M, Vallone R et al. Immediate occlusal loading of single lower molars using Branemark System Wide-Platform Ti-Unite implants: an interim report of a prospective open-ended clinical multicenter study. *Clin Implant Dent Relat Res* 2003; 5(Suppl 1):74-80.

6. Rocci A, Martignoni M, Gottlow J. Immediate loading in the maxilla using flapless surgery, implants placed in predetermined positions, and prefabricated provisional restorations: A retrospective 3-year clinical study. *Clin Implant Dent Relat Res* 2003; 5(Suppl 1):29-36.
7. Lorenzoni M, Pertl C, Zhang K et al. Immediate loading of single-tooth implants in the anterior maxilla. Preliminary results after one year. *Clin Oral Implants Res* 2003; 14(2):180-187.
8. Degidi M, Piattelli A, Gehrke P et al. Five-year outcome of 111 immediate non-functional single restorations. *J Oral Implantol* 2006; 32(6):277-285.
9. Piattelli A, Corigliano M, Scarano A et al. Immediate loading of titanium plasma-sprayed implants: An histologic analysis in monkeys. *J Periodontol* 1998; 69:321-327.
10. Piattelli A, Corigliano M, Scarano A et al. Bone reactions to early occlusal loading of two-stage titanium plasma-sprayed implants: A pilot study in monkeys. *Int J Periodontics Restorative Dent* 1997; 17(2):162-169.
11. Testori T, Szmukler-Moncler S, Francetti L et al. Immediate loading of Osseotite implants under submerged and immediate loading conditions in a single patient: A case report and interface analysis after 2 months. *Int J Periodontics Restorative Dent* 2002; 22:345-353.
12. Rocci A, Martignoni M, Burgos PM et al. Histology of retrieved immediately and early loaded oxidized implants: light microscopic observations after 5 to 9 months of loading in the posterior mandible. *Clin Implant Dent Relat Res* 2003; 5(Suppl 1):88-98.

13. Frost HM. A 2003 update of bone physiology and Wolff's law for clinicians. *Angle Orthod* 2004; 74:3-15.

Laboratory Colleague: Åsa Kämer, CDT, Manager of Dentalgruvan Dental Laboratory in Falun, Sweden.

Pär-Olov Östman, DDS, PhD



Dr. Östman received his dental degree from the University of Umeå, Sweden. He received his PhD degree in the department of Biomaterials, Institute for Surgical Sciences, Sahlgrenska Academy, Gothenberg University, Gothenberg, Sweden. He is head of "Team Holmgatan" private practice clinic in Falun, Sweden and Assistant Professor in the Department of Biomaterials, Institute for Surgical Sciences, Sahlgrenska Academy, Gothenberg University, Gothenberg, Sweden.

The age of digital dentistry for practical and aesthetic prosthetic solutions



Anders Örtorp, DDS, PhD
Associate Professor
Department Prosthetic
Dentistry/Dental Materials
Science, Institute of
Odontology, The Sahlgrenska
Academy, University of
Gothenburg, Sweden.

Our group in the prosthodontics department at the University of Gothenburg is looking very closely at the use of CAD/CAM technology to fabricate implant superstructures. This technology allows for milling prosthetic frameworks from a single block of titanium (or other material). Cylinders of such frameworks are not cast, but rather these are integrated within a single piece of titanium. Our research is confirming that such milled frameworks are very accurate. When restorative materials such as porcelain and acrylic are applied, and the porcelain is fired, problems with distortion do not occur (in contrast to the literature relating to porcelain application on conventional gold-alloy constructions).

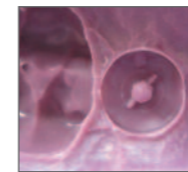
A good fit of the framework has several benefits. It enables a good preload and more predictability regarding accurate fit between implant restorative components and frameworks. Also, if the framework is highly accurate, it may be possible to omit one of the try-in appointments. Patients appreciate this time savings, as do clinicians.

In the future, I envision developments in digital dentistry that may eliminate the need for conventional impression making when fabricating implant superstructures. Here I believe that digital impressions such as the Encode® Impression System, will be useful. So far, no studies have been published evaluating master cast fabrication using impressions of the digitally coded abutment and robotic implant analog placement versus conventional impression techniques using impression copings. Our research group is currently investigating this subject. Advances in implant dentistry and the rapid development of digitized processes will continue, making computerized techniques more cost-effective and flexible. However more research is needed to further develop the digitized technique and improve its competitiveness.

We also hope to be able to present more evidence about the relationship of framework accuracy to the long-term prognosis of the prosthesis. We have one 10-year follow-up study recently published showing similar clinical results for milled titanium and cast gold-alloy constructions with very few framework fractures. We already know from our previous research that the predictability and long-term prognosis for implant treatment are excellent. In one recent study on the first generation of titanium frameworks, our group found a 15-year survival rate of 98.7% for implants placed in the lower jaw. This is an impressive accomplishment.

Increasing implant dentistry in undergraduate education using new technology: A pilot project

Hugo De Bruyn, MDS, MsC, PhD ± & Stefan Vandeweghe, DDS †



Although demographic factors and growing patient awareness of the benefits of dental implants have increased the need for dental schools to educate their students about implant treatment, university curricula have been slow to adjust. This article reports on a program recently implemented at the dental school of Ghent University in Belgium to expand undergraduate instruction in this area. The program utilizes new technology that simplifies implant restorations. A case illustrating the use of this technology is reported.

Key Words: implant dentistry, undergraduate dental education, Encode® Impression System, clinical training

Introduction

In daily dental practice, implants are well established as a means of replacing missing teeth in a large number of indications. Patient demand for implant treatment is also growing. Whereas implant dentistry was once considered a highly specialized treatment, routine implant procedures are increasingly being performed by general dentists who have acquired competence not only in prosthetics but also surgery. Given this paradigm shift, it is essential for newly graduated dentists to understand the possibilities and limitations of implant dentistry. This includes not only patient selection, treatment planning, and practical clinical implementation of the reconstructive therapy but also appropriate responses to technical and/or biological complications.

At both the undergraduate and postgraduate levels, university curricula have been slow to adjust to these developments. A recent review of European universities¹

assessed the status of dental implant education and addressed various aspects related to competence level, practical implementation, and barriers for further development in the field. The survey found that the average time assigned to implant dentistry was 36 hours, with a range of three to 120. Furthermore, the allocated time was dispersed among various courses (periodontics, prosthetics, oral diagnosis, oral imaging, oral and oral-maxillofacial surgery) and consequently rather theoretical in nature. Although 70% of the institutions that participated in the study claimed to offer their students clinical prosthetic training, this merely involved assisting others or receiving hands-on laboratory training. Only one-third of the students today are allowed during their dental training to perform prosthetic implant treatment, and in most cases this is limited to single-tooth restorations and/or overdenture treatment. Implant surgery is predominantly a part of postgraduate curricula

Hugo De Bruyn, MDS, MsC, PhD & Stefan Vandeweghe, DDS (continued)

and is available at 90% of the institutions. Fifty-three percent of the universities reported that undergraduate students do assist with surgery, but only 5% of the students at those universities actually treat patients.

Barriers for including prosthetics and surgery in dental curricula were primarily logistical such as lack of time (53%), funding (28%), or assisting staff (51%). General comments were that there are too many students for the limited number of patients who are able to comply with and pay for the proposed treatment. Academic institutions commonly struggle to find enough patients with a broad enough variety of treatment needs to allow for adequate student training. Given that implant training has the reputation of being more advanced, it may not be surprising that clinicians don't refer their patients for treatment by students. However, this implies that dental students are insufficiently prepared for the reality of today's dental practice.

The Rationale for Increasing Implant Dentistry

The rationale for increasing implant dentistry within the dental curriculum is largely based on demographic aspects. Estimates are that each year one million patients in Europe alone become edentulous. Despite advances in dentistry, the number of lost teeth still increases with age, and the need for care in those elderly patients will continue to grow. Additionally, treatment paradigms are changing. Conventional crown-and-bridge work is no longer considered to be the first choice. For single-tooth replacement, implant solutions are not only a more biological approach but also are comparable in cost to a three-unit conventional bridge when all factors are considered. Including this treatment modality in undergraduate curricula also complies with regulations that require patients be offered reasonable options.

Patient-centered thinking also provides an important argument for improving implant dental education. Edentulism is often associated with functional and aesthetic burdens and appears to have a negative impact on quality of life.² Tooth loss can also deeply affect patients' psycho-social well-being, even for patients who seem to adjust reasonably well to conventional dentures.³ Clinical studies indicate that not only technical aspects determine patient satisfaction with given treatments. Patient-related treatment outcomes may also be important determinants for patient satisfaction. These include perception of general comfort, aesthetics, masticatory function, and speech.⁴ Dierens et al⁵ found that more than

90% of the patients preferred a single-stage surgical approach to the classical two-stage delayed loading protocol.

A Team Approach

In the last decade, implant therapy has often been performed in conjunction with immediate provisionalization and immediate loading. These protocols require a highly effective collaboration between surgeons and restorative dentists, both pre- and post-surgically. Future dentists will need to know how to act as efficient team members and be able to perform treatment planning and pre-implant therapy. In a growing number of cases, both surgical and prosthetic procedures are being performed by one clinician, because this may simplify treatment planning and treatment. On the other hand, additional competencies may be required depending on the nature and complexity of the case. Dental students must learn their own limitations and understand the need to refer patients to specialists whenever necessary to ensure the best treatment. All these aspects must be included in dental education.

Educational Guidelines and Future Implementations

At a recently held consensus meeting organized by the Association for Dental Education in Europe (ADEE), there was widespread agreement among the academicians and implant-industry representatives about the urgent need to increase the penetration of implant dentistry within dental curricula.⁶ The following guidelines were proposed for implementation within European dental education:

- Future dentists should learn to incorporate oral implants into their overall treatment planning.
- They should understand basic aspects of healing and tissue integration, basic biomechanical and material-science principles, as well as surgical and prosthetic techniques.
- They should be prepared to continuously monitor the peri-implant tissues, render appropriate supportive therapy, and cope with biological and technical complications.
- The surgical technique for placing implants in straightforward cases should be included in the dental curriculum, while additional competence in the surgical phase should be required.
- The academic community should determine the levels and limitations to which the various aspects of implant dentistry and related skills are taught. Ethical and legal aspects of implant dentistry should not be forgotten.

Implementing Single-Implant Restoration in Undergraduate Education

As part of the implementation of these guidelines, the educational board of the dental school of Ghent University, Belgium, recently expanded the final year of undergraduate clinical education to include the practice of placing implants extraorally in artificial bone, performance of hands-on prosthetic procedures for single and overdenture cases, and flap creation and management using pig jaws. With a commitment from BIOMET 3i to provide surgical and prosthetic kits, dental implants, and abutments, it became possible to further implement these acquired preclinical skills in clinical practice. Because of time constraints, it was essential to choose straightforward cases and provide a prosthetic solution that was valid for all students and all cases. Furthermore, it was the aim of this course to instruct students in implant-restorative treatment for a common clinical situation.

Patients with a single missing maxillary tooth with two intact neighboring teeth were thus recruited via e-mail from university hospital personnel. They were to receive tooth replacement with a NanoTite™ Tapered Implant (BIOMET 3i) and an implant-supported restoration created using the Encode® Impression System (BIOMET 3i). This practical solution limits the number of visits required for treatment. Students must be able to complete their cases prior to graduation, so a maximum four- to six-month time framework is essential.

Potential patients were clinically and radiographically screened, and a waiting list was created. Prior to final inclusion, patients were also treated for any remaining tooth or soft-tissue problems. At the start of the academic year, every student was assigned a patient and expected to adhere to the following learning steps.

1. At an initial consultation, the student plans the presurgical steps necessary to restore the remaining natural teeth to a periodontally healthy condition. Periapical as well as orthopantomographic radiographs are taken, study casts are obtained, and clinical pictures are taken to document the dental condition and aesthetic appearance. This information is downloaded in the student's portfolio for evaluation by the teaching staff.

2. Periodontal pretreatment (e.g. scaling, root planing, and tooth extraction) is performed, oral hygiene instructions are given, and the patient is re-evaluated prior to surgery.
3. A surgical guide is fabricated.
4. The radiographic analysis is performed, and the implant position, length, and diameter are selected. This presurgical planning is downloaded in the portfolio.
5. On the day of surgery, the student checks the instruments and reviews the case and drilling procedures with his or her professor; prior to administering a local anesthetic.
6. The student creates a full-thickness flap, prepares the implant osteotomy, places the implant and appropriate Encode Healing Abutment, and secures the flap with sutures. The patient is given post-operative instructions and dismissed.
7. After one week, the sutures are removed, oral hygiene instructions are reviewed, and follow-up appointments are scheduled.
8. After four months, the prosthetic procedure is initiated by making an impression of the Encode Healing Abutment. Although the Encode Impression System eliminates the need to make an implant-level impression with an impression coping, the student does so at this point to become familiar with the more traditional implant-restorative procedure. An opposing jaw impression is also made, and an occlusal registration is performed, along with a shade selection. The work order for the dental technician is filled in, and the impression is sent to the BIOMET 3i PSP Department.
9. The casts are scanned, and a definitive Encode Abutment is designed virtually, then milled from a solid blank of titanium. A robot inserts an implant analog into the master cast, and the definitive Encode Abutment is inserted.
10. The dental laboratory receives the Robocast and the definitive Encode Abutment and uses these to fabricate the definitive restoration.
11. One week later, the definitive Encode Abutment is seated and secured with a Gold-Tite® Abutment Screw (BIOMET 3i) tightened to 20Ncm of torque. The definitive crown is cemented. The patient is released with oral hygiene instructions and appointments for follow-up care.

Hugo De Bruyn, MDS, MsC, PhD & Stefan Vandeweghe, DDS (continued)

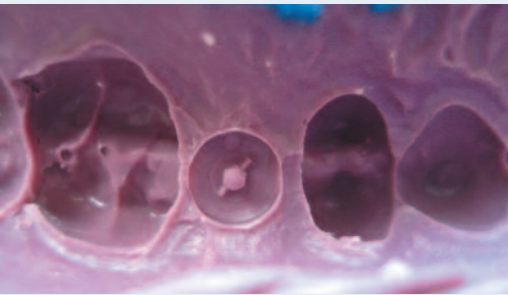


Fig. 1
Intaglio surface of the definitive impression that accurately reproduced the codes on the occlusal surface of the EHA.

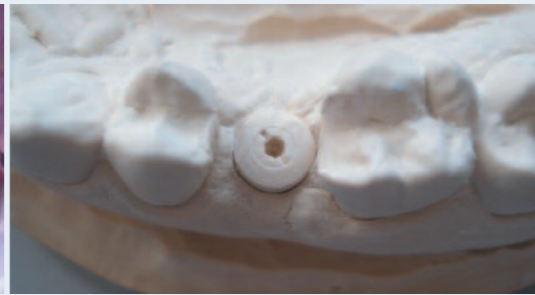

Fig. 2
Occlusal surface of the EHA, duplicated in dental stone, in the master cast.

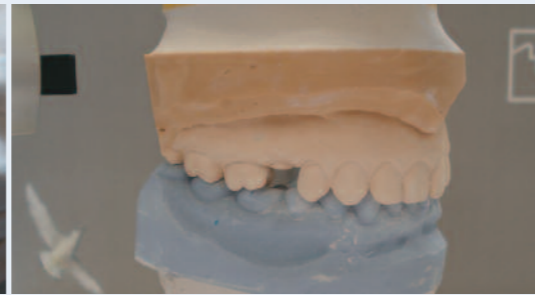

Fig. 3
Lateral image of the articulated casts in the articulator. The mounted casts, not the articulator, were sent to the BIOMET 3i PSP Department.




Fig. 4
3Shape Laser Optical Scanner.

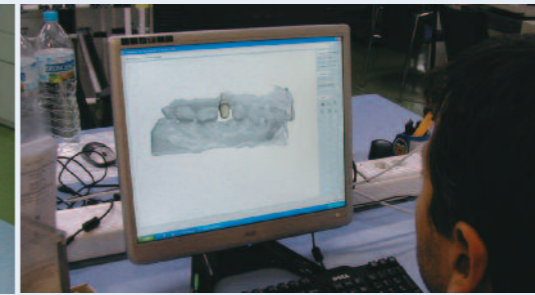


Fig. 5
Image of one step in the process of the computer-aided design of the definitive Encode® Abutment.

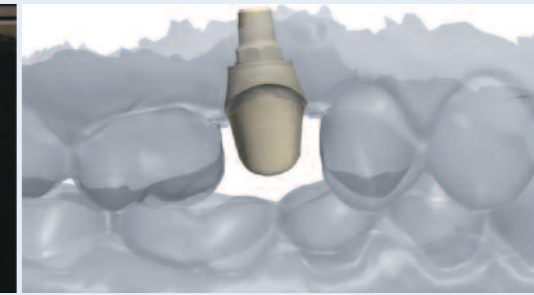


Fig. 6
Digital image of the buccal aspect of this specific Encode Abutment within the virtual articulation of the mounted casts.

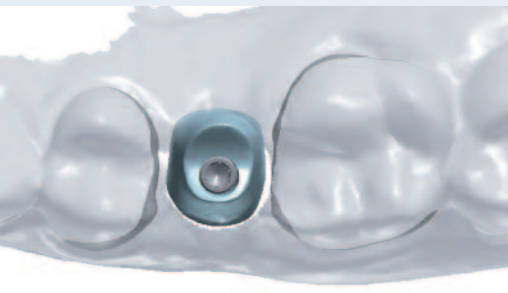


Fig. 7
Digital image of the occlusal aspect of the specific Encode® Abutment in the virtual maxillary cast.



Fig. 8
Laboratory image of the CNC machine milling the definitive Encode Abutment.



Fig. 9
Laboratory image of the definitive Encode Abutment just prior to removal from the milling unit.

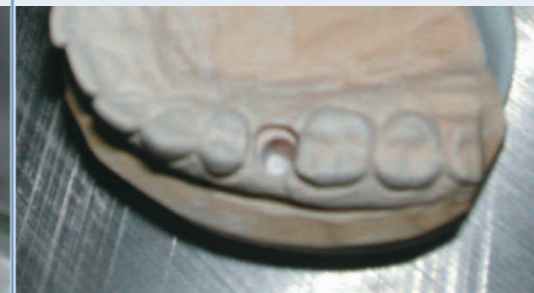

Fig. 10
Laboratory image of the maxillary cast after the stone was removed by the robot.

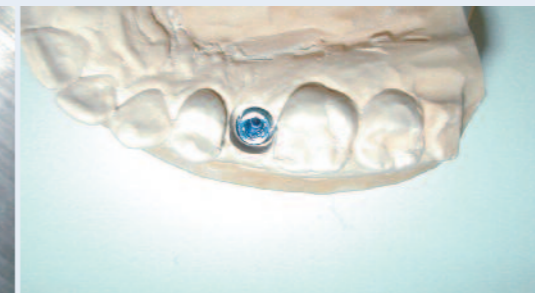


Fig. 11
Occlusal laboratory image of the implant lab analog correctly positioned within the Robocast.

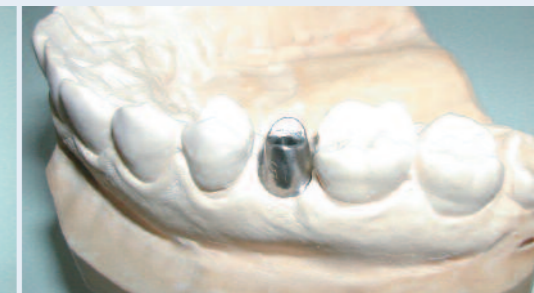

Fig. 12
The definitive abutment was placed onto the Robocast and evaluated for fit, axial wall taper, marginal design, and overall finish.

Clinical Case Presentation

The following case illustrates the use of the Encode Impression System to achieve optimal aesthetics for a single-implant crown.

The patient was a 38-year-old female who presented with a 4mm diameter Certain® Implant (BIOMET 3i) placed into the No. 4 [15] tooth position six months previously. The implant had been placed in a single-stage approach; an Encode Healing Abutment (EHA) was placed at the time of implant placement.

The implant was determined to be stable, immobile, and surrounded by healthy peri-implant soft tissues. The codes on the EHA were noted to be supragingival circumferentially. A polyether impression was made of the EHA (Fig. 1). The clinician verified that the codes on the occlusal surface of the EHA were recorded in the

impression. These codes contain vital information regarding the implant/abutment connection, implant restorative platform, emergence profile of the EHA, and the three-dimensional position of the implant, including the hex orientation.

The impression was sent to the dental laboratory, where it was poured using a Type IV dental stone, and a master cast was fabricated (Fig. 2). The casts were mounted on an articulator with Adesso Mounting Plates (Fig. 3). The mounted casts were sent to the BIOMET 3i PSP Department in Valencia, Spain.

A PSP technician placed the casts into a 3Shape Laser Optical Scanner (Fig. 4). Using specialized computer software, the definitive Encode Abutment was designed in accordance with the clinician's directions (Figs. 5-7).

The data were sent to a computer numerically controlled (CNC) milling machine; the definitive abutment was milled from a blank of titanium alloy (Figs. 8 & 9). In a separate process, but using the same digitized data from the laser optical scan, a robot removed stone from the maxillary master cast in the area of the EHA stone replica (Fig. 10). A technician placed the corresponding implant analog into the robotic arm, and the robot placed the implant lab analog into the precise position as dictated by the optical scan (Fig. 11). The analog was luted in place with light-cured cyanoacrylate cement.

The definitive Encode Abutment was placed onto the Robocast and evaluated (Fig. 12). It was found to be satisfactory relative to the inter-occlusal clearance, axial wall taper; and marginal design (chamfer). The casts and definitive abutment were packaged and returned to the commercial laboratory for fabrication of the definitive all-ceramic crown.

The patient returned to the clinic and the Encode Healing Abutment was removed from the implant. The implant was stable, and the peri-implant soft tissues were free of inflammation. The definitive Encode Abutment was placed with a try-in screw (Fig. 13), and a radiograph was taken. The restoration was tried in (Fig. 14), interproximal contacts were adjusted as needed, and another radiograph was taken to verify that the crown was completely seated onto the abutment (Fig. 15). The occlusion was adjusted for centric contacts. The crown and abutment were removed, and the crown was polished. The retaining screw securing the definitive Encode Abutment was tightened to 20Ncm of torque. The crown was cemented with temporary cement, and a final radiograph was verified to confirm complete removal of the excess cement. The patient was given oral hygiene instructions and released.

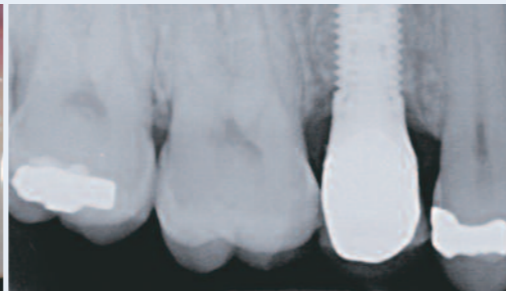
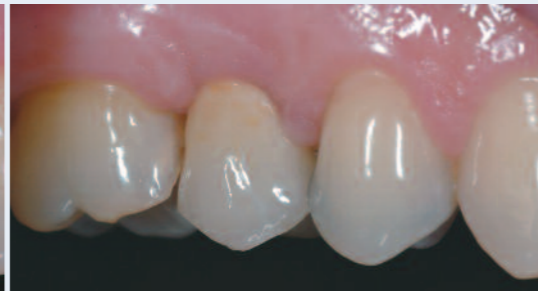
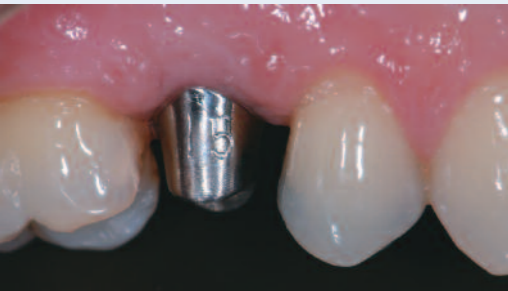
Fig. 13
Definitive Encode® Abutment in place intraorally.

Fig. 14
Clinical image of the crown in place on the definitive Encode Abutment.

Fig. 15
Radiograph demonstrating that the definitive crown was correctly seated onto the abutment.

Clinical Relevance

In implant dentistry, proper abutment selection is crucial for aesthetic and functional success. An ideal abutment supports the peri-implant soft tissues, and the margins follow the gingival contours. This allows clinicians to easily and predictably remove excess cement. Placement of a definitive Encode Abutment, as illustrated in this clinical case presentation, meets these requirements and reduces soft-tissue concerns associated with conventional impression procedures.

References

1. De Bruyn H, Koole S, Mattheos N et al. A survey on undergraduate implant dentistry education in Europe. *Eur J Dent Educ* 2009;13 (Suppl 1):3-9.
2. Strassburger C, Kerschbaum T, Heydecke G. Influence of implant and conventional prostheses on satisfaction and quality of life: a literature review. Part 2: Qualitative analysis and evaluation of the studies. *Int J Prosthodont* 2006;19:339-348.
3. Fiske J, Davis DM, Frances C et al. The emotional effects of tooth loss in edentulous people. *Br Dent J* 1998;184:90-93.
4. Al-Omiri M, Hantash RA, Wahadni AA. Satisfaction with dental implants: a literature review. *Implant Dent* 2005;4:399-406.
5. Dierens M, Collaert B, Deschepper E et al. Patient-centered outcome of immediately loaded implants in the rehabilitation of fully edentulous jaws. *Clin Oral Implants Res* 2009;20:1070-1077.
6. Mattheos N, Albrektsson T, Buser D et al. Teaching and assessment of implant dentistry in undergraduate and postgraduate education: a European consensus. *Eur J Dent Educ* 2009;13(Suppl 1):10-17.

Hugo De Bruyn, MDS, MsC, PhD ±



Prof. De Bruyn is Professor and Chairman of the Department of Periodontology and Implantology at the University of Ghent, Belgium. He is responsible for undergraduate education and is also the director of the accredited specialist program in periodontology and the postgraduate implant program. He is also a visiting professor at the Department of Prosthetic Dentistry at the University of Malmo, Sweden. Prof. De Bruyn also holds memberships in the Academy of Osseointegration and American Academy of Periodontology.

Stefan Vandeweghe, DDS †



Dr. Vandeweghe graduated as a dentist in 2006 from the University of Ghent, Belgium. Today he is working in a private practice and at the University of Ghent, with a focus on implant surgery and prosthetics. He is involved in education and research at the department of periodontology and oral implantology and is currently working on his PhD thesis.

JIRD Digital
www.JIRD-online.com



Get instant access to the digital edition of JIRD to view the current issue, as well as archived issues.

An online version of the Journal of Implant and Reconstructive Dentistry (JIRD), is available at www.JIRD-online.com.

Go Online To Sign-Up To Receive A Digital Subscription To JIRD.

Once registered, subscribers will be alerted via e-mail when the next issue of JIRD is available for viewing.

Interactive Format

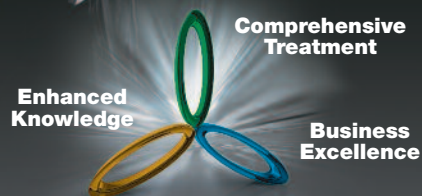The online version of the journal features expanded content, treatment videos and interviews with key opinion leaders in the field of implant and reconstructive dentistry. The interactive format provides site visitors with an experience similar to that of reading a printed publication,

but with more interactive elements, such as a zoom feature and embedded videos. Users are able to access a single article to view or download and print, searched by issue or author.

Environmental Friendly

Having an online presence thus allows JIRD to be instantly disseminated to a global audience in a manner that conserves the earth's precious resources. Each issue is archived perpetually, allowing JIRD to serve as an electronic reference library, with easy searchability.

**Want More?
Solutions Start
Here!**



Introducing Solutions For Success

- Comprehensive Treatment Solutions
- Enhanced Knowledge Solutions
- Business Excellence Solutions



Providing Solutions – One Patient At A Time™

Our Solutions Offer:

- Patient Driven Implant Systems
- End-To-End Prosthetic Solutions
- Site-Specific Regenerative Options
- Comprehensive Educational Continuum For All Levels Of Expertise
- Diversified Delivery Options
- Audience-Specific Program Options
- Patient Recruitment Support
- Business Efficiency Support
- Practice Growth Support

BIOMET 3i™
PROVIDING SOLUTIONS – ONE PATIENT AT A TIME™

Call Your BIOMET 3i Representative Today To Find Out How We Can Help You Provide Solutions – One Patient At A Time. In The USA: 1-800-342-5454. Outside The USA: +1-561-776-6700

Or Visit Us Online At: www.biomet3i.com

Providing Solutions – One Patient At A Time and design are trademarks of BIOMET 3i LLC. BIOMET 3i and design are trademarks of BIOMET, Inc. ©2010 BIOMET 3i LLC. All rights reserved.